

FINISHING THE APICAL ONE-THIRD: ENDODONTIC CONSIDERATIONS

by Clifford J. Ruddle, D.D.S.

The purpose of the "RUDDLE ON ROTARY" series of articles is to provide useful information that will enable dentists to predictably shape root canals for three-dimensional obturation. The information in these articles is intended to help clinicians better understand how to safely use nickel-titanium (NiTi) rotary files. This author's articles previously published in *Dentistry Today* described the concepts that form the foundation for successfully preparing root canal systems.^{1,4} This article will briefly review the ProTaper system and technique, and will then focus on the various considerations that will influence predictability and success when finishing the apical one-third.

THE PROTAPER SYSTEM

The NiTi ProTaper rotary instruments (*Dentsply Tulsa Dental*) represent a new generation of files for shaping root canals (*Figure 1*).^{4,6} The ProTaper system is designed to provide the fewest number of instruments that can efficiently and safely

prepare a fully tapered shape. The ProTaper concept is logical, the instrument sequence is simple to understand, and the technique is easy to learn. The series is comprised of just three shaping and three finishing instruments. The three ProTaper shaping instruments have increasing percentage tapers over the length of their active blades. The three finishing instruments have variable D_0 diameters, different fixed percentage tapers in their apical extents, and then decreasing percentage tapers in the coronal two-thirds of their active blades. Other innovative design features of the ProTaper six-instrument set include a convex triangular cross-section, efficient cutting angle, continuously changing pitch and helical angles, variable D_0 diameters, modified guiding tips and short handles. In combination, these desirable features significantly improve NiTi rotary performance by affording better flexibility, enhanced efficiency and improved safety (*Figure 2*). To better understand and fully appreciate the ProTaper geometries, features and benefits, the reader is encouraged to review a previous "RUDDLE ON ROTARY" ProTaper article.³



Figure 1. The ProTaper NiTi rotary set of files is comprised of just three shaping and three finishing instruments.

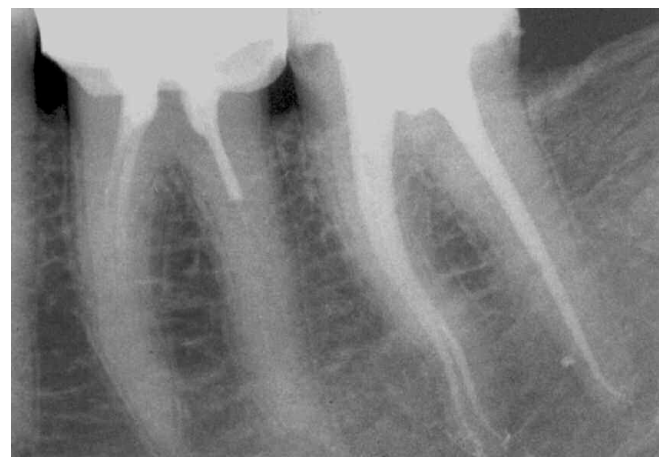


Figure 2. The canals of this endodontically treated mandibular second molar were exquisitely shaped with ProTaper files and demonstrate smooth flowing, multi-planar curvatures. (Courtesy of Dr. Dominique Martin; Paris, France)

THE PROTAPER TECHNIQUE

Root canal preparation procedures are simplified and improved when there is straightline access to the orifice(s) (*Figure 3*). The ProTaper technique for shaping a root canal begins by first negotiating the coronal two-thirds with 10 and 15 hand files (*Dentsply Maillefer*) until a smooth, reproducible glide path is confirmed. The coronal two-thirds can be optimally pre-enlarged by first utilizing the Shaper 1 (S1) then the Shaper X (SX) ProTaper rotary files. Importantly, the S1 file expands the glide path so that the apical extent of the SX file does not engage, rather passively follows. With the coronal two-thirds of the canal fully prepared, then excellent radicular access facilitates negotiating and finishing the apical one-third of the canal. Previous articles detailed the importance of intracanal irrigants and how to negotiate the apical one-third, establish and maintain patency, confirm working length and verify the glide path.^{2,4} When a smooth, reproducible glide path to the terminus of the canal is confirmed, then the ProTaper sequence is to carry the S1 then the Shaper 2 (S2) to length. The S1 and S2 expand, smooth and refine the apical one-third glide path and promote the safe use of the ProTaper Finisher 1 (F1) which, in many instances, will complete the preparation. When indicated, the ProTaper Finisher 2 (F2) and/or Finisher 3 (F3) are available to finish larger canals and serve to smoothly blend the apical one-third of the preparation into the middle one-third. The ProTaper finishing criteria was previously discussed and may be utilized to guide each case to successful completion.^{4,6} The following portions of this article will focus on the various considerations that influence success when finishing the apical one-third.

FINISHING THE APICAL ONE-THIRD

The apical one-third of a root canal can be finished once it has been negotiated to length, patency established and the foramen enlarged to at least a size 15 hand file. The *sine qua non* of excellence in canal preparation is consistently finishing the

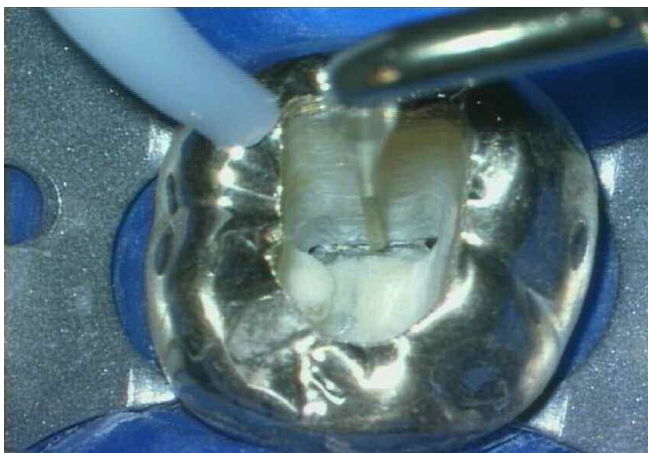


Figure 3. A photo demonstrates the visual advantage using an abrasively coated ProUltra ENDO-3 ultrasonic instrument without water (*Dentsply Tulsa Dental*) to progressively sand, smooth and finish the access preparation.

apical one-third. The ideal “finished” preparation will always exhibit a uniform taper that progressively narrows toward its terminal extent.^{7,8} Importantly, canals that have been optimally shaped promote both three-dimensional “cleaning” and “obturation” (*Figure 4*).

HAND VS. ROTARY FINISHING

When a 15 or larger file is confirmed at length, a decision on whether to use hand or rotary instruments to finish the apical one-third can be made. It is wise to finish a root canal preparation with hand instruments when a system exhibits difficult anatomy, certain resorptive defects or an iatrogenic problem. Small flexible files may be utilized to scout the apical one-third and provide information regarding canals that abruptly merge, excessively curve, significantly recurve, dilacerate or divide. In general, certain canals exhibit anatomical challenges that necessitate a reciprocating handle motion in order to move a precurved 15 file to length (*Figures 5a, b*). In these instances, the apical one-third of a canal should be finished with *hand instruments*. However, if a straight, flexible, stainless steel 15 file can be gently pushed over a few millimeters and can passively slide to length, then *rotary NiTi instruments* can be employed to “finish” the apical one-third of the canal. At times, difficult canals can be progressively enlarged with hand files until a smooth and predictable glide path to the terminus can be established in which case rotary instruments may become suitable for finishing (*Figure 5c*).

Irregular Glide Path: Hand Files

When there is an irregular glide path, regardless of etiology or the size of the foramen, then 0.02 tapered hand instruments should be used to prepare and finish the apical one-third of a canal. When the length of the canal has been carefully scouted and fully negotiated to its radiographic terminus with sizes 10 and 15 files, then the apical one-third can be finished with 0.02 tapered 20-60 hand files. Sizes 20, 25 and 30 flexfiles

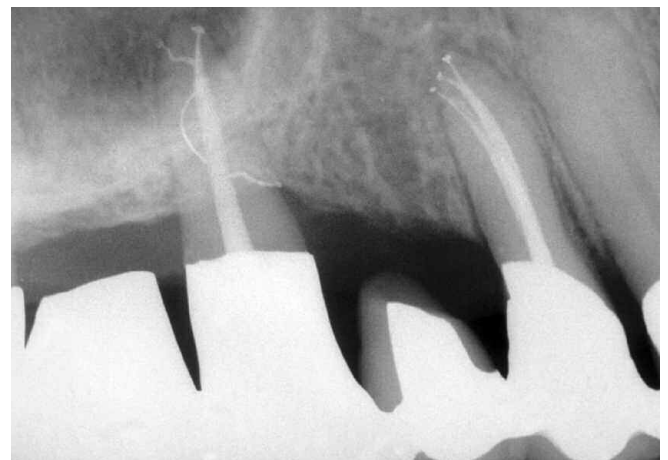

Figure 4. Three-dimensional endodontic treatment is the foundation of perio-prosthetics.

(Dentsply Maillefer) may be selected to initiate apical one-third procedures as advantageously these stainless steel files have improved flexibility and their non-cutting tips allow them to safely follow an existing pilot hole. All stainless steel instruments that are carried into the apical one-third must be precurved to simulate the anticipated curvature of the canal based on well-angulated, pre-operative radiographs and clinical information. NiTi hand files sizes 35-60 (Dentsply Maillefer) may be advantageously selected because their unmatched flexibility provides greater safety and control in creating deep shape and finishing the apical one-third of the canal. As an alternative to finishing the apical one-third with 0.02 tapered hand files, a knurled mandrel (Dentsply Maillefer) can be placed over the handle of any of the three ProTaper finishing files so they can be utilized manually in a rotary motion. If there is a canal wall irregularity, then depending on its location and extent, it may be necessary to curve the larger NiTi files to promote the mechanical shaping and cleaning objectives.

Hand files may be utilized to progressively enlarge, blend and create uniform taper in the apical one-third of the canal. Specifically, *gauging* and *tuning* with ISO 0.02 tapered instruments is a technique directed towards confirming a uniform taper in the apical one-third of the root canal preparation.^{2,7,9} The clinician begins to *gauge* the most apical cross-sectional diameter of the canal when a hand or rotary instrument just snugs into the terminus and resists further apical travel. In order to prove with certainty that the diameter of the file at length represents the true size of the foramen, the clinician must then *tune*. Tuning is the clinical activity of recapitulating through a series of successively larger instruments and working them until they are observed to uniformly back out of the canal (Figure 6a). Clinically, the file that snugs in at length represents the true most apical cross-sectional diameter of the canal if, and only if, each successively larger instrument uniformly backs out of the canal in 1/2 mm intervals (Figure 6b).

If increasingly larger instruments do not uniformly step back from the canal terminus, then "finish" by re-utilizing all the

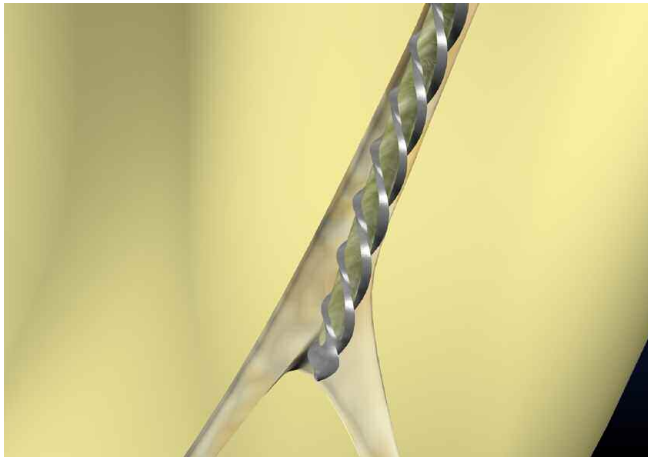


Figure 5a. A graphic illustrates the potential problem of immediately trying to negotiate tighter, more restrictive canals to length.

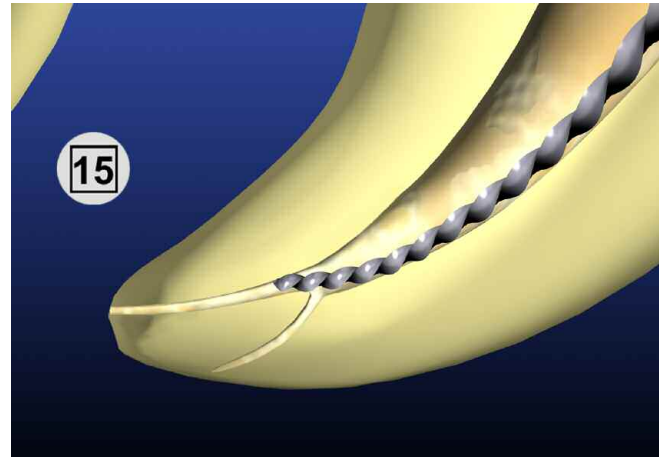


Figure 5b. A graphic illustrates that a pre-enlarged canal can more readily accommodate a precurved file and improve the predictability of achieving length.

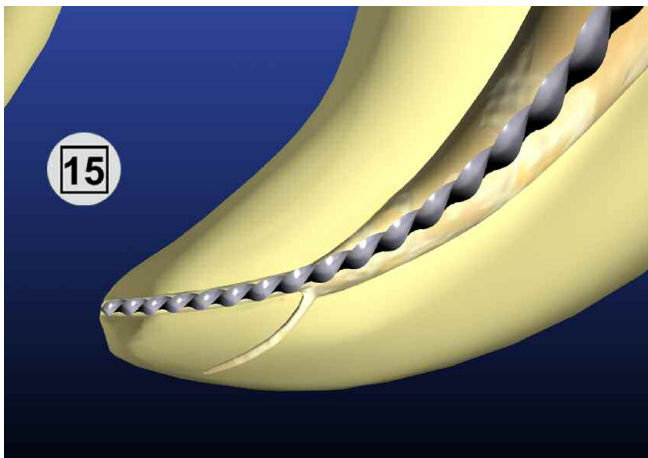


Figure 5c. A graphic illustrates that a 15 file can be utilized to determine if there is a smooth reproducible glide path to safely accommodate a rotary shaping file.

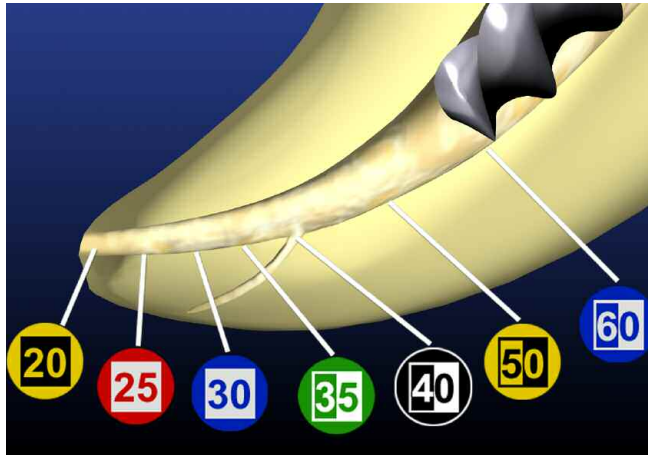


Figure 6a. A graphic illustrates that gauging and tuning procedures verify deep shape and confirm a “finished” preparation.

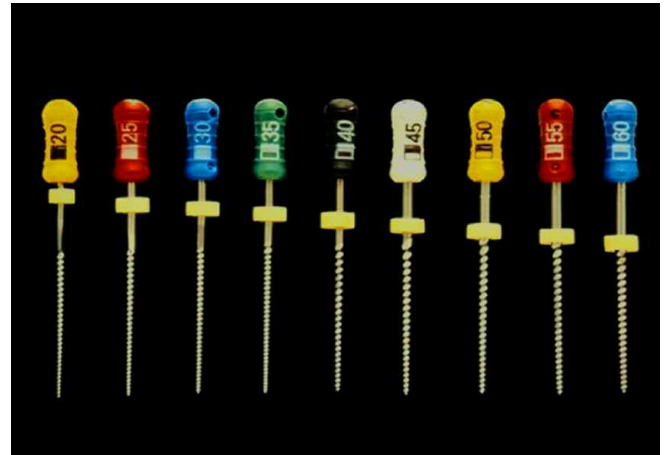


Figure 6b. A photograph illustrates that if the 20 file is at length, then each consecutively larger instrument uniformly steps out of the canal.

instruments in the series that worked short of the foramen.⁸ In more difficult cases, recapitulate through the entire series again, and perhaps yet again, to create an extraordinary clean, smooth flowing and evenly tapered preparation. Many times when performing shaping procedures, the clinician is just one recapitulation away from excellence. Gauging and tuning verify “deep shape” and create the opening for three-dimensional cleaning and obturation (Figure 7).⁹

Smooth Glide Path: ProTaper Rotary Files

When a smooth, reproducible glide path to the terminus is confirmed with hand files and after the S1 and S2 have been carried to length, then the apical one-third can be finished. In many cases, only one ProTaper finishing file will be required to create the optimal deep, fully tapered shape. Specifically, following the use of the ProTaper 20/07 F1 to the terminus, the size of the foramen is gauged using a 20/02 hand file (Figure 8). When gauging the size of the foramen, passively slide the hand file to length and gently tap on the handle, in

an apical direction, to determine if the file is snug or loose at length. When gauging the foramen with a hand file, never rotate or reciprocate its handle as this motion will serve to engage the cutting blades into dentin, screw the file long and needlessly over-enlarge the foramen.

If the 20 hand file is snug at length then the canal is fully shaped and, if irrigation protocols have been followed, ready to pack. If the 20 hand file is loose at length, only then should the clinician proceed to the next sequentially larger ProTaper finishing instrument, which is the 25/08 F2. Following the use of the F2 to length, the size of the foramen is gauged by using a 25/02 hand file (Figure 9). If the 25 hand file is snug at length then the canal is fully shaped and, again, if irrigation protocols have been followed, ready to pack. If the 25 file is loose at length, then and only then, should the clinician proceed to the next sequentially larger ProTaper finishing instrument, which is the 30/09 F3. Following the use of the F3 to the terminus of the canal, the foramen is gauged utilizing a 30/02 tapered hand file (Figure 10). If the 30 hand

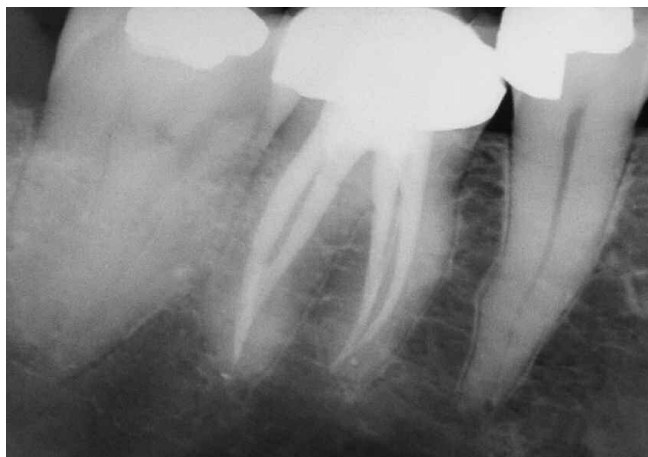

Figure 7. The canals of this endodontically treated mandibular first molar were gauged and tuned, and the pack demonstrates the uniform and fully tapered shapes.

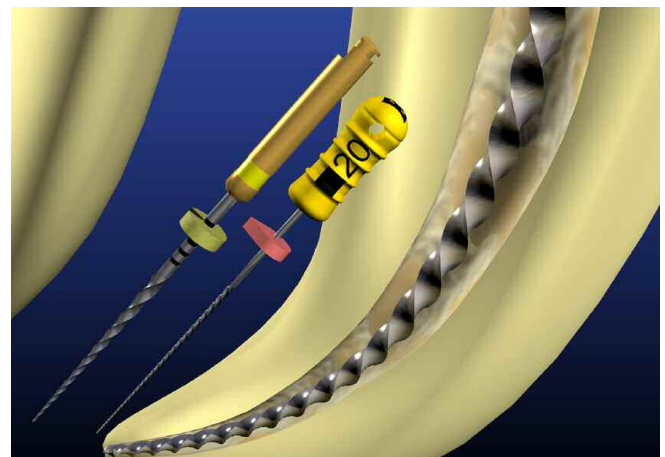


Figure 8. Following the use of the 20/07 F1 rotary file to length, the foramen is gauged using a 20/02 hand file.

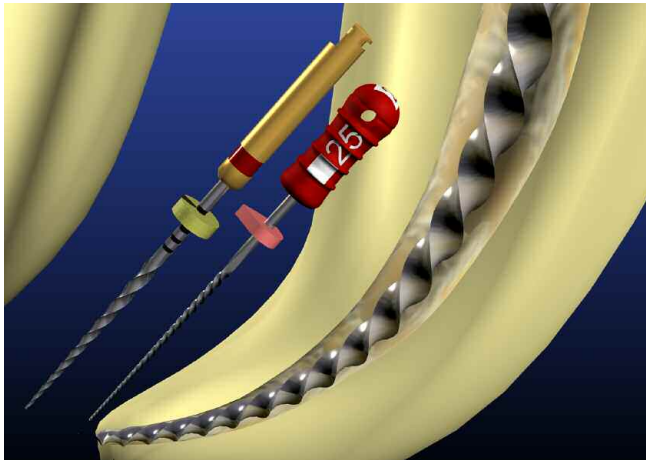


Figure 9. Following the use of the 25/08 F2 rotary file to length, the foramen is gauged using a 25/02 hand file.

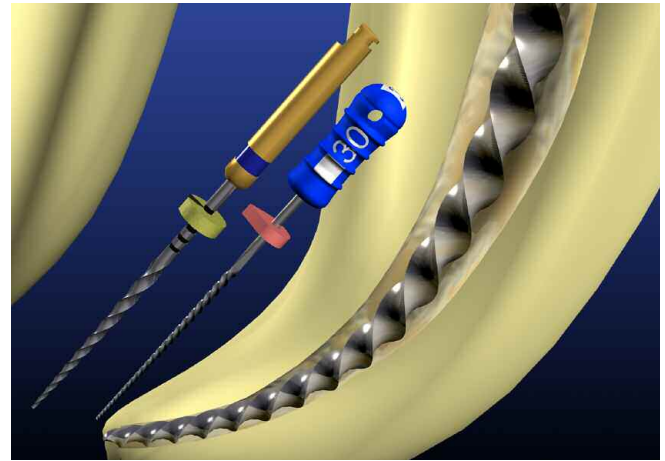


Figure 10. Following the use of the 30/09 F3 rotary file, the foramen is gauged using a 30/02 hand file.

file is snug at length then the canal is optimally shaped and, again, if irrigation protocols have been followed, ready to pack. If the 30 hand file is loose, then the next section will address how to finish these more open and typically straight-forward canals.

FINISHING LARGER SYSTEMS

In instances where the foramen is gauged and determined to be greater than 0.30 mm, and a smooth glide path has been verified, then an alternative NiTi rotary file line may be used. The decision as to which specific line of instruments to select should be based on cutting efficiency, flexibility and safety. Importantly the instruments chosen and the techniques employed must create deep shape and the resistance form to hold gutta percha during three-dimensional obturation (*Figure 11*). Research evaluating canal cleanliness compared to apical one-third shape has clearly shown that preparations need to taper at least 0.06 mm/mm to ensure that a sufficient volume of irrigant over an adequate interval of time can efficaciously circulate and clean into the canal anatomy.⁷⁻¹⁰ Except in larger and straighter canals, rotary files that have D_o diameters greater than 0.30 mm and tapers greater than 6% are frequently too stiff to safely place into the apical one-third of a more curved root canal. As such, NiTi rotary 0.02 tapered files or 0.04 tapered ProFiles (*Dentsply Tulsa Dental*) will provide the flexibility to safely shape the apical extent of these larger, more open canals. As noted with hand files, NiTi rotary 0.02 and 0.04 tapered files can be employed in a step-back technique to create virtually any tapered shape that is desired.

EXPAND THE DEEP SHAPE

There are cases when a ProTaper 20/07 finishing file is snug at length, the foramen is confirmed to be 0.20 mm after gauging with a 20/02 hand file, yet the clinician may find it advantageous to expand the deep shape of the canal. In the instance where the F1 was at length, then a fuller shape can be easily and safely accomplished by carrying the F2 two (2) mm short and the F3, three (3) mm short of the working length. This

clinical method of carrying each larger ProTaper finishing file progressively shorter than the previous one will maintain the size of the foramen while expanding the overall shape in the middle and apical one-thirds of the canal.⁶ This step-back method is not done routinely and is only appropriate when different, well-angled radiographs confirm that the dimensions of a root canal safely accommodate a fuller shape.

TROUBLESHOOTING THE APICAL ONE-THIRD

Many endodontic complications can potentially occur when preparing the apical one-third of a canal, and as such, many techniques have been developed and clinically shown to manage these iatrogenic events.¹¹ The apical one-third of the root canal system is typically a more challenging region to prepare. Anatomically, this region of the canal is tighter, more curved, and divisions are commonly present (*Figure 12*). Traditionally, most canals were prepared using files and gates glidden drills, and as such, the potential for iatrogenic events, including blocks, ledges, apical transportations, perforations and broken instruments, were ever present.¹² Fortunately, NiTi rotary shaping files have virtually eliminated most of these iatrogenic events. However, some of this euphoria has been offset by the potential for NiTi rotary files to break or to, a lesser extent, transport the foramen. The remaining portion of this article will focus on the factors influencing NiTi breakage, apical transportations, and how to prevent these mishaps.

FACTORS INFLUENCING NITI BREAKAGE

There are many factors that will individually and in combination influence file breakage.¹³ The clinician who understands the causes of file separation will have a greater appreciation for how to prevent breakage.

File Design

There are numerous design features that directly impact the performance of any given NiTi rotary file line. Some of the more important mechanical features include the percentage

taper of an instrument, whether a file is fixed versus variably tapered, and if a file has a negative, neutral or positive rake angle. Other critical features of a file that influence performance are cross-sectional geometry, tip configuration, the length of cutting blades, and the helical angle and pitch of the cutting flutes. These design features influence flexibility, cutting efficiency and safety. Additionally, the design of an instrument will dictate whether a file is too stiff to follow a glide path or has a tendency to screw and get inadvertently pulled into a canal. Further, the design will influence how many recapitulations are required for a file or a series of files to safely achieve length.

RPM

Each brand of NiTi rotary files has a recommended speed to ensure optimal performance. Clinicians need to select an electric motor that will allow them to utilize the rotary files they choose at the recommended RPM. When a NiTi rotary file is used at a speed slower than recommended the instrument tends to lose cutting efficiency and bogs down during use. Another potentially negative result of using a speed lower than recommended is increased friction which can lead to rotary file failure. On the contrary, when a NiTi file is used at a speed faster than recommended then the instrument tends to become more dangerous as it can grab and screw into the canal predisposing to breakage.⁶ The ProTaper files should be run at a speed of 300 RPM to ensure optimal performance.

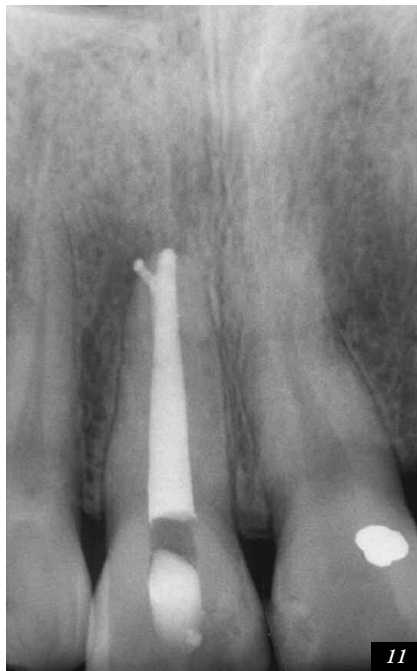Torque

Torque is the amount of rotation that a force exerts on an object and is measured in gram centimeters (g.cm). The "rotation to failure" torque is measured by turning a file that has been grasped and immobilized at D₃ at a constant RPM.¹⁴

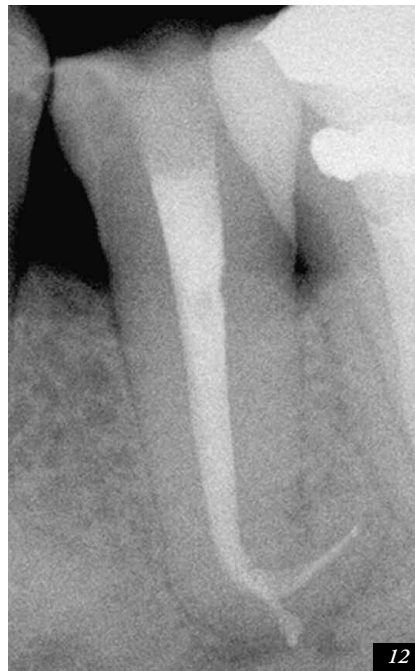The "mean working" torque may be defined as the torque required for any given NiTi file to cut dentin. The safety quotient (SQ) is a ratio where the *rotation to failure* torque is divided by the *mean working* torque, and ideally, should provide values greater than one (1).¹⁵ The SQ formula has been typically used to evaluate fixed tapered files which oftentimes engage dentin toward their smaller, weaker, and less active cutting blades. On the contrary, the new ProTaper progressively tapered shaping files are designed to engage and cut dentin on their larger, stronger and more active blades. As such, if the SQ formula is to provide useful information, then the data used for calculation must be indexed to the specific location where each ProTaper instrument has been designed to cut dentin.¹⁶ Torque control electric motors are intended to optimize file performance and safety, and have generally been programmed for fixed tapered files. When a smooth, reproducible glide path has been confirmed, research has shown that the ProTaper shaping files, in combination with the Tecnika motor (*Dentsply Tulsa Dental*), can work safely at maximum torque and provide SQ values greater than one (1).

Stress & Strain

The strength of a material depends on its mechanical properties, which include elasticity, hardness and stiffness. The strength of a file may be described by how much force it can resist without permanently changing its shape. Endodontically, when a rotating file engages tooth structure, *stress* within the file results and can be defined as the internal force within the instrument to resist the external force to cut dentin. If the file cannot resist an external force, then the NiTi metal changes its shape or uniformity, and this is known as *strain*. Specifically, when a rotary file is working in a curved canal, the engaged portion of the instrument is subject to stresses.



11



12

Figure 11. An endodontically treated maxillary central incisor demonstrates that a shaped canal provides resistance form to achieve three-dimensional obturation.

Figure 12. This endodontically treated mandibular second bicuspid demonstrates a smooth flowing dilacerated preparation, apical bifidity and the ProTaper advantage. (Courtesy of Dr. Fabio Gorni; Milano, Italy)

Tensile stress occurs on the file's outer curvature and the metal stretches. At the same time, compressive stress occurs on the file's inner curvature resulting in the metal compressing. These combined stresses unite and make the instrument bend. The ProTaper shaping files have increasingly larger percentage tapers over the length of their blades whereas the ProTaper finishing files have decreasingly smaller percentage tapers from D_4 - D_{14} . This design feature increases flexibility and, importantly, decreases both the frictional stress and the potential for file breakage (*Figure 13*).¹⁶

Reproducible Glide Path

Nickel-titanium rotary files should only be used in portions of the canal that have a confirmed, reproducible glide path. To assure there is available space within a canal for rotary instruments to follow, stainless steel 0.02 tapered sizes 10 and 15 hand files should be employed. Small hand instruments are primarily used to gather reconnaissance information, to confirm available space, or when necessary, to create sufficient space prior to using more efficient rotary NiTi instruments.^{3,4} Appreciate the 10 and 15 hand files have D_{16} diameters of 0.42 and 0.47 mm, respectively, and can create considerably more space than the numerical number on their handles would suggest (*Figure 14*). The secret for safely using NiTi rotary instruments is to thoughtfully, deliberately and, in more calcific canals, repeatedly use smaller sized hand files until sufficient space exists for rotary files to follow.⁹ A NiTi rotary file is designed to "follow" a canal as its non-cutting and most flexible working end is guided by a pilot hole of circumferential dentin. When it is confirmed that a 15 file can gently and predictably slide through any part of a root canal, then this "secured" region can be safely prepared using NiTi rotary files.

Vertical Force / Pressure

When used as directed, most rotary files will follow a canal that has a confirmed, reproducible glide path. Because each different brand of files has its own specific designs and

geometries, different techniques have been recommended to maximize safety and cutting efficiency. In use, fixed percentage tapered instruments have a greater potential for taper lock which results when the entire length of a file's cutting blades inadvertently engages dentin. Taper lock contributes to greater torsional stress, alloy fatigue and potential for file breakage. Importantly, research has shown that fixed tapered instruments with radial lands require four times more vertical force to cut dentin than progressively tapered files without radial lands.¹⁶ Fixed tapered instruments are oftentimes used in a pecking or pumping action to avoid being inadvertently pulled into the canal. On the contrary, a progressively tapered shaping file engages a smaller zone of dentin and is used with a lateral brushing action with virtually no apical pressure.⁹ Importantly, this method of use reduces the potential for taper lock, torsional stress, and the potential for breakage.

Speed of Penetration

Another variable in NiTi rotary file breakage is the speed of penetration in which an instrument is deployed into a canal. The speed of penetration is influenced by the insertion pressure and the design of the file. As an example, instruments with full or relieved radial lands have a greater surface area that contacts dentin as compared to files with a convex triangular cross-section. Additionally, files with fixed tapers generally have a greater surface area that contacts dentin compared to variably tapered files. As such, if the speed of penetration is too quick in combination with a relatively large, engaged contact area, then there is increased friction and potential for breakage. Further, friction and the potential for breakage increases when a file is pushed too quickly into a canal because as the blades clog, the displacement of cut dentin is diminished. ProTaper files are variably tapered, have a convex triangular cross-section and a continuously changing helical angle and pitch over their active blades. When used as directed, these design features enhance cutting efficiency, improve auguring debris out of the canal and, importantly, reduce the potential for any give file to inadvertently screw into the canal.

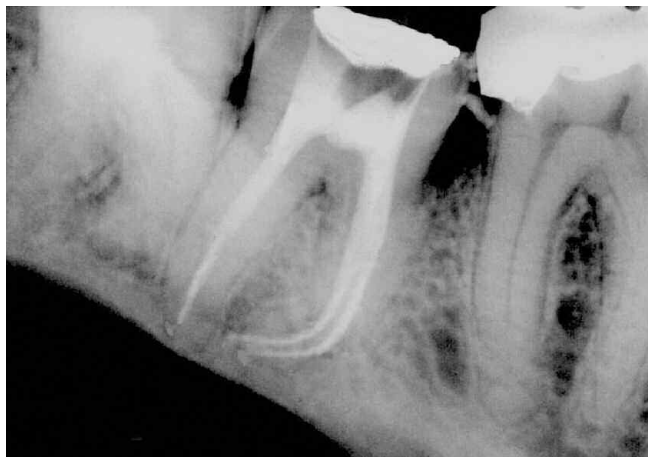

Figure 13. This endodontically treated mandibular second molar demonstrates that ProTaper files can smoothly and safely shape difficult, apical one-third curvatures. (Courtesy of Dr. Edmond Koyess; Beirut, Lebanon)



Figure 14. A photograph showing ISO 0.02 tapered 10, 15 and 20 files. Each instrument tapers 0.32 mm over its 16 mm of cutting blades.

Root Canal System Anatomy

It must be recognized that certain root canals exhibit anatomical configurations which preclude the safe use of NiTi rotary files. Scouter files can provide information regarding root canal system anatomy. Clinicians need to appreciate the five commonly encountered anatomical forms, which include canals that merge, curve, recurve, dilacerate or divide (*Figure 15*). Scouter files provide information regarding the anatomy and give important feedback regarding the canal's degree of *curvature*, *recurvature*, or if there is a *dilaceration*. Further, before introducing rotary instruments, clinicians need to know if a single canal coronally subsequently *divides* or if two or more systems within a root *merge* along their length.

Lubrication

No file should be introduced into the root canal space until the appropriate irrigant is placed into the pulp chamber.¹⁷ Typically, before beginning NiTi rotary procedures, clinicians fill the chamber with sodium hypochlorite (NaOCl). To further reduce the friction between the rotary instrument and the wall of the canal, some clinicians advocate filling the pulp chamber brimful with NaOCl then additionally dipping the active portion of a NiTi rotary file in a viscous chelator. Lubricating agents reduce friction and promote the maintenance of the glide path for rotary files to follow.

Directions for Use

Each brand of instruments has its own specific directions for use. These guidelines are intended to minimize clinical breakdowns, such as a broken file. Typically, the work of a rotary NiTi instrument can continue as long as the file will passively feed deeper into the canal. When a file will not passively advance then it should be immediately withdrawn and the clinician should recognize there may be insufficient canal diameter, intracanal debris, intrablade debris, or difficult anatomy. In addition, a rotary file may not be able to passively advance deeper into a canal if the distal extent of the file is too stiff to follow the anatomical configuration of the canal. One of the

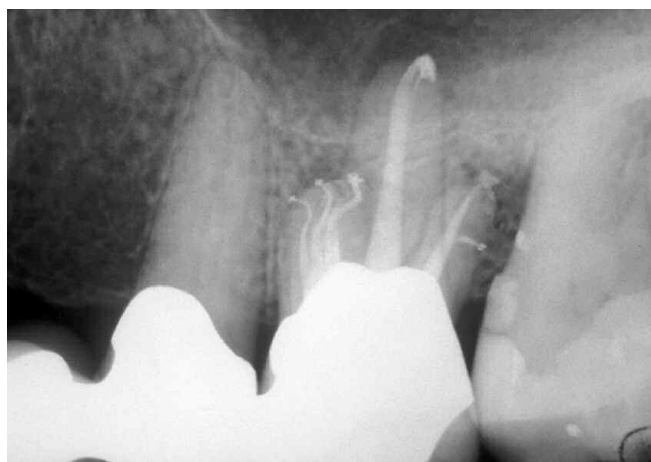

Figure 15. An endodontically treated maxillary first molar demonstrates five treated canals and that each system exhibits various anatomical configurations.

critical distinctions of the NiTi ProTaper system is that the three shaping files (i.e. SX, S1 and S2) were designed to rapidly cut dentin using a deliberate brushing action on the withdrawal stroke.^{4,6,9} Specifically, the ProTaper technique is to let the shaping files passively float into a canal until their apical advancement ceases. Strategically, the instrument is then lifted away from the terminus about one (1) mm and used to selectively cut dentin, in a lateral brushing motion, on the outstroke. A brush-cutting motion can be used to optimally relocate the coronal portion of the canal away from furcal danger, improve straightline radicular access, and importantly, reduce the dangerous rotation to failure torque oftentimes associated with breakage (*Figure 16*).^{9,16}

Multiple vs. Single Use

During use, any given NiTi rotary file should be inspected for wear and its cutting blades frequently cleaned to optimize efficiency and reduce the potential for breakage.¹⁸ One of the major causes of NiTi rotary instrument breakage, besides "method of use", is "multiple use".⁷ In the author's opinion, all files are disposable and should be discarded after each case due to metal fatigue and loss of cutting efficiency. Additionally, files wear during work and rotation to failure is influenced by the length, diameter and curvature of any given canal.¹⁹ The concern with cost, associated with the disposable instrument concept, may be offset by adding \$30-\$40 to the endodontic fee. Advantageously, starting each case with a new set of files provides confidence and allows sharp instruments to cut dentin more efficiently, reducing torsional loads on the file during use.

APICAL TRANSPORTATIONS

Moving the anatomical position of the foramen to a new iatrogenic location on the external root surface equates to an external transportation of the canal. Foraminal rips, zips, or tears are caused by carrying progressively larger and stiffer files to length.^{7,12} If a transportation has occurred, then the canal exhibits reversed apical architecture and fails to provide resistance form to hold gutta percha during obturation. An apical transportation contributes to post-operative problems, wet canals, and poorly packed cases that are vertically overextended but internally underfilled.

The causes of apical transportations can be attributable to inappropriate cleaning and shaping concepts. Techniques advocating negotiating the entire length of the canal first encourage aggressive cutting action and actually promote blocks, ledges, transportations and apical one-third perforations.^{9,11,12} When a clinician has negotiated a canal with small hand files then typically working length is confirmed with either a radiograph or an electronic apex locator (*Root ZX, J. Morita Corporation*). However, this recorded working length progressively changes and shortens because subsequent shaping procedures create a more direct path to the terminus. One of the significant advancements in root canal preparation techniques is to understand and appreciate the importance of pre-enlarging the coronal two-thirds of a canal.^{2,7,9} Pre-enlargement procedures create a more direct path to the foramen so when working length is established, it will be more accurate and is less likely to change when finishing the apical one-third of the canal. An accurate

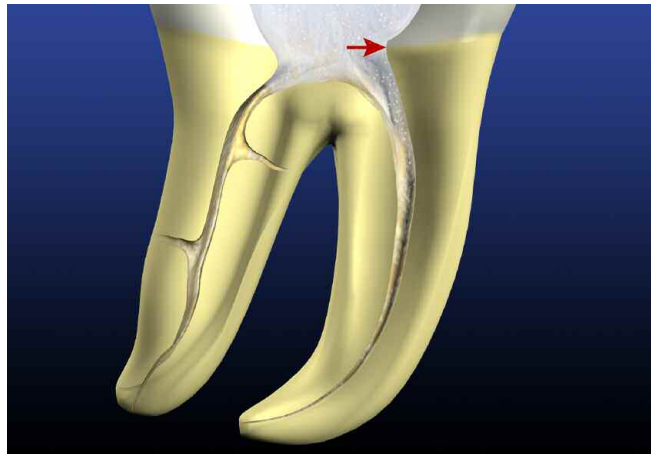

Figure 16a. Furcated teeth have internal triangles of dentin which should be removed during the initial stages of treatment to facilitate shaping procedures.

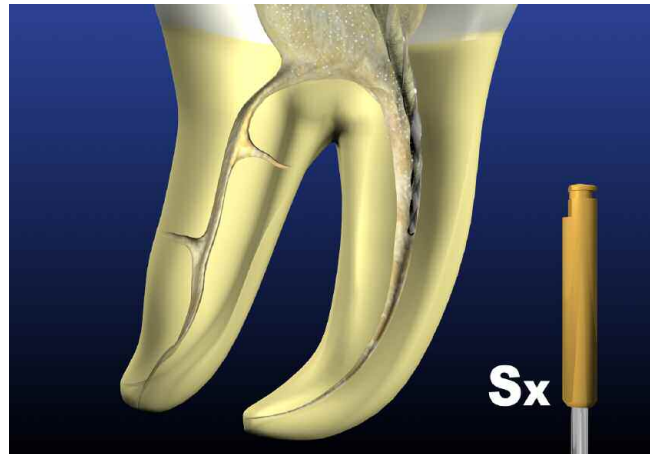


Figure 16b. The ProTaper SX file is used in a brushing motion to cut dentin and safely relocate canals away from external root concavities.

working length will reduce the potential for an apical transportation as subsequent instruments are less likely to be carried beyond the foramen.

It is unwise to pass any NiTi rotary instrument through the foramen, especially in a more curved canal. As has been stated earlier, one of the fundamental principles of successfully using NiTi rotary files is to understand their more flexible and non-cutting tips are guided by a pilot hole of circumferential dentin. If a portion of a rotary file extends beyond the foramen, then there is no pilot hole to guide the instrument. Rotary NiTi instruments are manufactured straight, have shape memory and will begin to straighten when they are extended beyond the foramen of more curved canals. The potential for apical transportations is further heightened because the greater tapered NiTi rotary files exhibit rapidly increasing diameters and get much stiffer away from their terminal extents. Additionally, pumping or rotating an instrument at length, or repeatedly carrying the same instrument to length, especially in more curved canals, predisposes the file to cut dentin on the outer wall of the canal which invites a ledge and/or apical transportation. When a NiTi rotary instrument achieves length, it should be immediately withdrawn as the shape is cut.

CONCLUSION

This article has identified various factors that will influence success when finishing the apical one-third of a root canal. There are many new NiTi rotary file lines emerging on the market. Brand names like K3, RaCe and ProTaper files represent the new generation of files and, although quite different in design, they are beginning to replace the older generations of instruments. Erroneously, these more efficient instruments are at times labeled dangerous, aggressive, or technique sensitive. This misinformation is already being refuted as ongoing scientific research and clinical articles are being published. In the final analysis, are the new instrument designs aggressive or efficient? The answer is always education and training. Regarding the label "aggressive versus efficient" reminds me of the baseball quote "It's not the bat, it's the batter." William James had it right when he said, "A new idea is first condemned as ridiculous and then dismissed as trivial, until finally, it becomes what everybody knows." ▲

REFERENCES

1. Ruddle CJ: Nickel-titanium rotary systems: Review of existing instruments and geometries, *Dentistry Today* 19:10, pp. 86-95, 2000.
2. Ruddle CJ: Current concepts for preparing the root canal system, *Dentistry Today* 20:2, pp.76-83, 2001.
3. Ruddle CJ: The protaper endodontic system: geometries, features and guidelines for use, *Dentistry Today* 20:10, pp. 60-67, 2001.
4. Ruddle CJ: The protaper technique: endodontics made easier, *Dentistry Today* 20:11, pp. 58-68, 2001.
5. West JD: Introduction of a new rotary endodontic system: progressively tapered files, *Dentistry Today* 20:5, pp. 50-57, 2001.
6. Martin D, Amor J, Machtou P: Mechanized endodontics: the protaper system, principles and clinical protocol, *Revue d'Odonto Stomatologie* 31:1, pp. 33-42, 2002.
7. Ruddle CJ: Ch. 8, Cleaning and shaping root canal systems. In Cohen S, Burns RC, editors: *Pathways of the Pulp*, pp. 231-291, 8th ed., Mosby, St. Louis, 2002.
8. Schilder H: Cleaning and shaping the root canal system, *Dent Clin North Am*, 18:2, pp.269-296, 1974.
9. Ruddle CJ: "Ruddle on Clean•Shape•Pack", 2-tape video series, Studio 2050, producer. Santa Barbara, California: Advanced Endodontics, 2002.
10. Berutti E, Marini R: A scanning electron microscopic evaluation of the debridement capability of sodium hypochlorite at different temperatures, *J Endod* 22:9, pp. 467-470, 1996.
11. Ruddle, C.J: "Ruddle on Retreatment", 4-tape video series. James Lowe Productions, producer. Santa Barbara, California: Advanced Endodontics, 2000.
12. Ruddle CJ: Ch. 25, Nonsurgical endodontic retreatment. In Cohen S, Burns RC, editors: *Pathways of the Pulp*, pp. 875-929, 8th ed., Mosby, St. Louis, 2002.
13. Sattapan B, Palamara JEA, Messer HH: Torque during canal instrumentation using rotary nickel-titanium files, *J Endod* 26:3, pp.156-160, 2000.
14. Council on Dental Materials and Devices: New american dental association specification n° 28 for endodontic files and reamers, *JADA* 93, pp. 813-817, 1976.
15. As proposed by Dr. John T. McSpadden (rxroots.com).
16. Blum JY, Machtou P, Ruddle CJ, Micallef JP: The analysis of mechanical preparations of extracted teeth using protaper rotary instruments: value of the safety quotient. Submitted and approved for publication in *Int Endod J*, 2002.
17. Berutti E, Marini R, Angeretti A: Penetration ability of different irrigants into dentinal tubules, *J Endod* 23:12, pp. 725-727, 1997.
18. Yguel-Henry S, von Stebut J: Cutting efficiency loss of root canal instruments due to the bulk plasticdeformation, surface damage and wear, *J Endod* 20:8, pp. 367-372, 1994.
19. Sattapan B, Nervo GJ, Palamara JEA, Messer HH: Defects in rotary nickel-titanium files after clinical use, *J Endod* 26:3, pp. 161-165, 2000.