

LOCATING CANALS

STRATEGIES, ARMAMENTARIUM AND TECHNIQUES

by Clifford J. Ruddle, DDS

Over the past decades, many technologies have come to market to help dentists better perform each procedural step that comprises start-to-finish endodontics. Yet, many of these technological advancements are irrelevant if a clinician cannot identify any given orifice, underlying canal, and its related root canal system. As such, there is great value in those technologies that promote diagnostics and vision, which serve to improve the probability of identifying mineralized or aberrant canals, or in the retreatment situation, a previously missed canal.

Predictable endodontic treatment begins with an effective access preparation that enables locating any given orifice, which in turn, promotes negotiating, securing, and shaping the canal, 3D disinfection, and filling this root canal system. Missed canals hold pulp tissue, and at times bacteria and related irritants, which oftentimes contribute to clinical symptoms and lesions of endodontic origin (*Figure 1*). This article will look at the anatomical considerations within the various tooth groups, then focus on strategies for locating canals.

ANATOMICAL CONSIDERATIONS

Teeth may be categorized as to whether they are maxillary vs. mandibular, anterior vs. posterior, or single vs. multi-rooted. Further, harbored within root structure is what Schilder referred to as the root canal system. Let's review root canal morphology within the various tooth groups.¹

Maxillary Central and Lateral Incisors. On occasion, maxillary incisors may contain more than one canal.² Further, these teeth can also radiographically display an anomaly, termed dens invaginatus or dens in dente, which is a tooth within a tooth (*Figure 2*).

Maxillary 1st and 2nd Bicuspid. Maxillary 1st bicuspid generally have separate buccal and lingual roots. However, the 1st bicuspid can, at times, radiographically exhibit mesiobuccal

(MB), distobuccal (DB), and palatal roots (*Figure 3*). Maxillary 2nd bicuspid generally have a single, broad root, measured buccal to lingual. Although the orifice is commonly ribbon-shaped, clinicians must appreciate that broad canals oftentimes exhibit deep canal divisions.³

Maxillary 1st and 2nd Molars. Maxillary 1st molars have at least two systems in the MB root more than 90% of the time. According to the literature and clinical experience, the MBI and MBII systems can communicate via an isthmus, merge, or have their own individual apical portals of exit (*Figure 4*).⁴ Maxillary 2nd molars should be suspected of having a second canal in the MB root until proven otherwise.

Mandibular Incisors. The mandibular incisors have broad roots measured facial to lingual. These broad roots hold a second more lingual canal approximately 45% of the time.⁵ Access cavities should be carried more lingual at the expense of the cingulum to locate and treat this potential system (*Figure 5*).

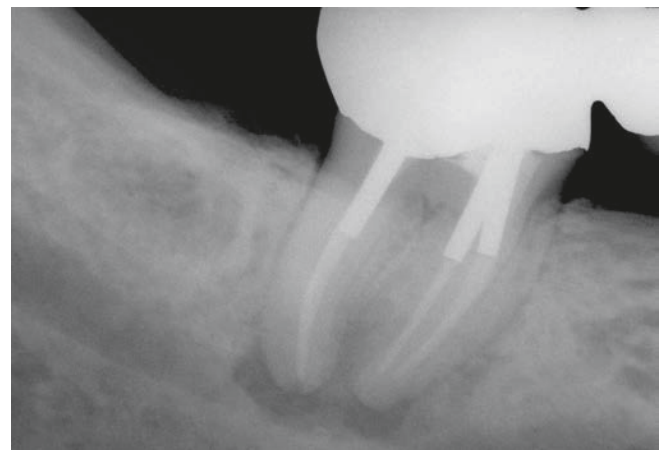


Figure 1a. A pre-operative radiograph of this second molar bridge abutment demonstrates three posts, previous endodontics, and apical pathology.

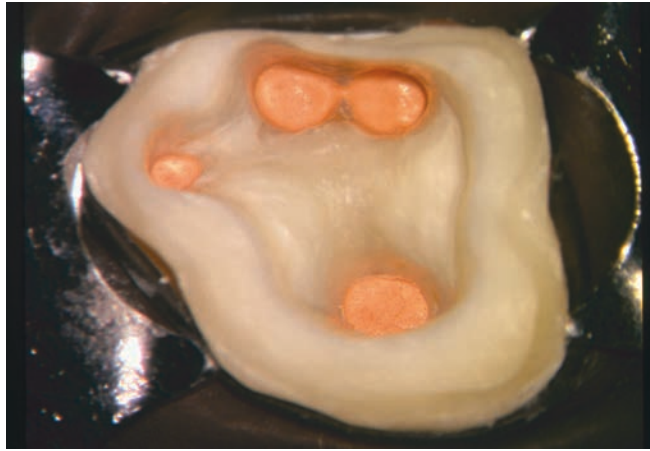


Figure 1b. The access preparation is shown following disassembly and 3D cleaning, shaping and obturation procedures. Note the displaced more MLII orifice.

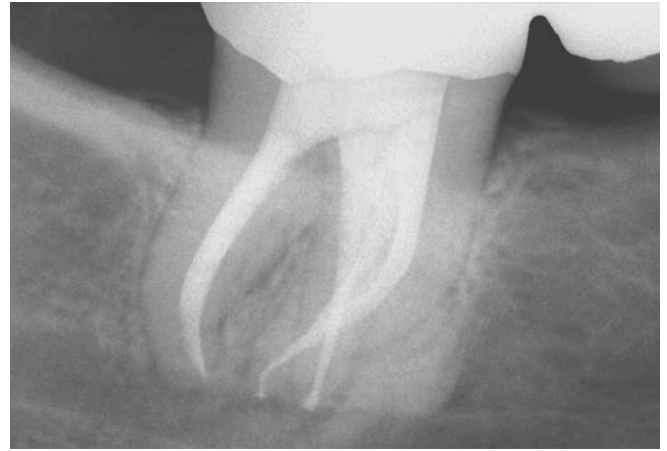


Figure 1c. A recall radiograph demonstrates the revisional endodontic treatment, the displaced MLII system, and the new restorative effort.

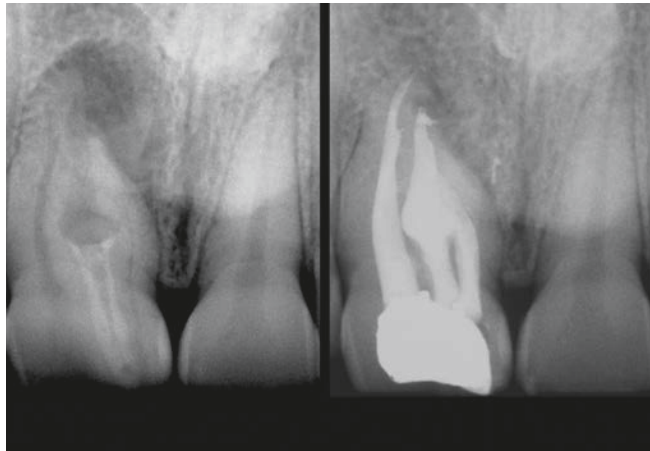


Figure 2. Left: A radiograph of the maxillary right central incisor suggests dens in dente, internal resorption, multiple canals, and a large asymmetrical lesion. Right: A 6-month recall reveals multiple filled systems and progressive apical and lateral osseous repair (courtesy of Dr. Francesco Mangani; Rome, Italy).

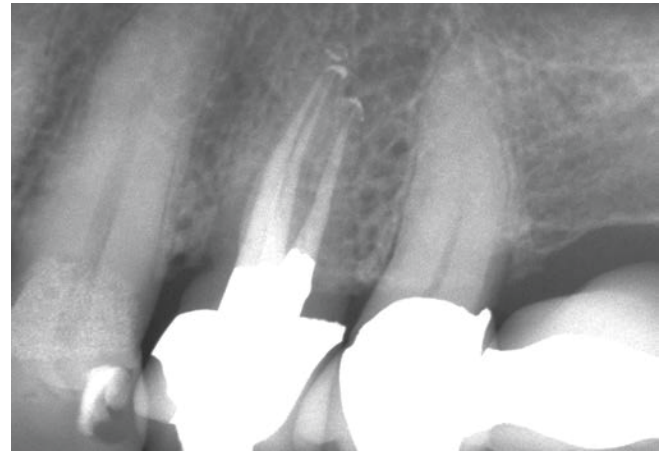

Figure 3. This radiograph demonstrates endodontic treatment of a maxillary 1st bicuspid with 3 roots and related systems.

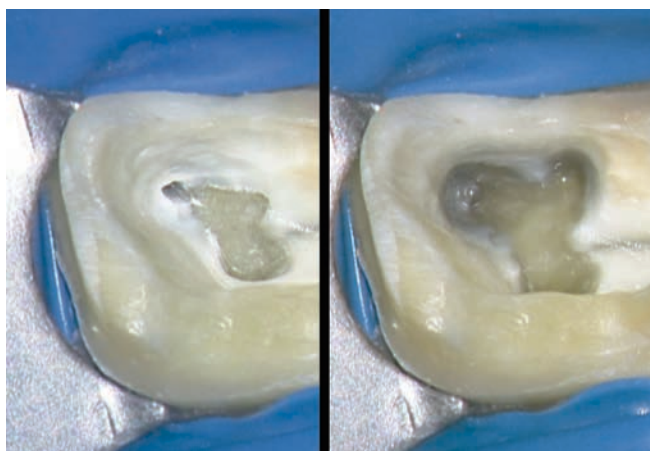


Figure 4a. Left: This photo reveals the MBI and related groove and the DB orifices. Note how color maps the pulpal floor anatomy. Right: This photo demonstrates the pre-shaped MBI and MBII systems following the elimination of the overlying shelf of dentin.

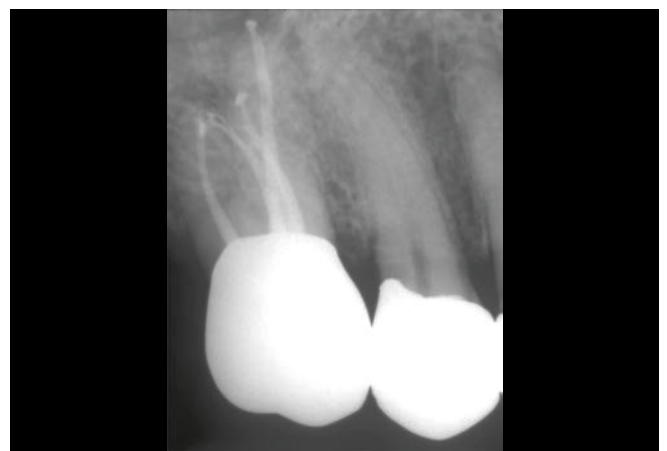

Figure 4b. A radiograph reveals 4 filled systems. Specifically, note the deep MBI bifidity, the separate MBII system, and the provisionalized casting.

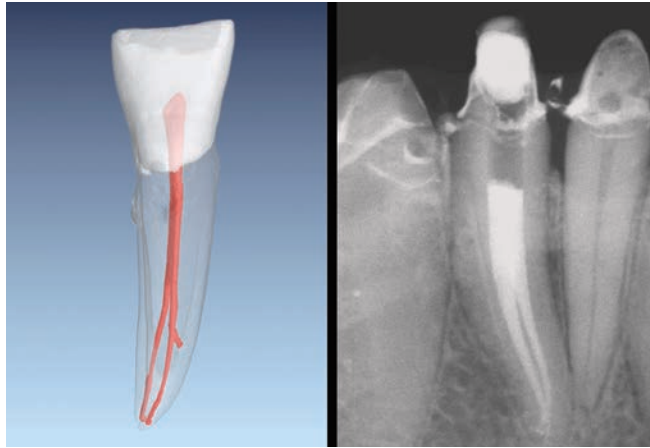


Figure 5. A μ CT image of a mandibular incisor (courtesy of Dr. Frank Paque; Zurich, Switzerland). This radiograph reveals an abutment tooth with similar anatomy.

Mandibular Bicuspid. This group of teeth typically exhibits one root that notoriously holds complex root canal systems. The anatomical variations include displaced orifices, deep divisions, loops, branches, and multiple apical portals of exit (**Figure 6**).⁶ Infrequently, but on occasion, extra roots are noted.

Mandibular 1st and 2nd Molars. These teeth routinely have significant anatomical variations.¹ On occasion, the mesial root may hold a third system which may be located within the groove between the MB and mesiolingual (ML) orifices (**Figure 7**), or a 3rd mesial root canal may be displaced (**Figure 1**).⁷ The typically broad distal root commonly contains a second canal which may be separate along its length or become contiguous following shaping procedures. Infrequently, but on occasion, a separate distolingual (DL) or DB root is detected radiographically, termed radix entomolaris or radix paramolaris, respectively.⁸

C-Shaped Molars. Dentists need to be familiar with this aberrant tooth form, typically found in mandibular 2nd molars. C-shaped molars exhibit distinct features and their in-

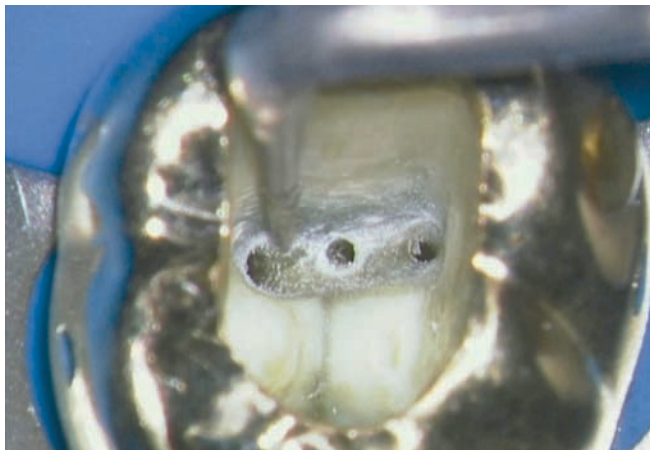


Figure 7a. Microsonic instrumentation may be used to track and explore grooves, trough for hard-to-find orifices, and uncover hidden canals, such as this mid-mesial.

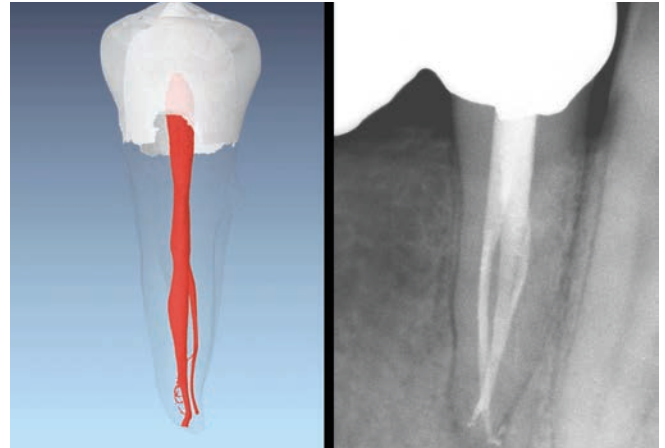


Figure 6. A μ CT image of a mandibular bicuspid (courtesy of Dr. Frank Paque; Zurich, Switzerland). A post-operative film demonstrates similar complex anatomy.

cidence within population groups is well known (**Figure 8**).⁹ Radiographically, this tooth exhibits a fused root, a deep pulp chamber, and a cul-de-sac furcation that opens toward the lingual aspect. Clinically, the ML orifice is isolated; however, the MB orifice is connected to the distal orifice by a thin ribbon-shaped communication that ultimately extends along the pulpal floor from the MB to the DL aspect, making a C-shaped configuration.

STRATEGIES FOR LOCATING CANALS

With a greater appreciation of the endodontic anatomy within in the various tooth groups, let's look at specific methods that may be utilized to identify more mineralized, aberrant, or previously missed canals. The following represents, in no particular order, the more important strategies for locating any given orifice, canal, and its related root canal system.

Anatomical Familiarity: Any dentist can become a serious student of endodontic anatomy by visualizing the historic work of Walter Hess or visualizing state-of-the-art μ CT images

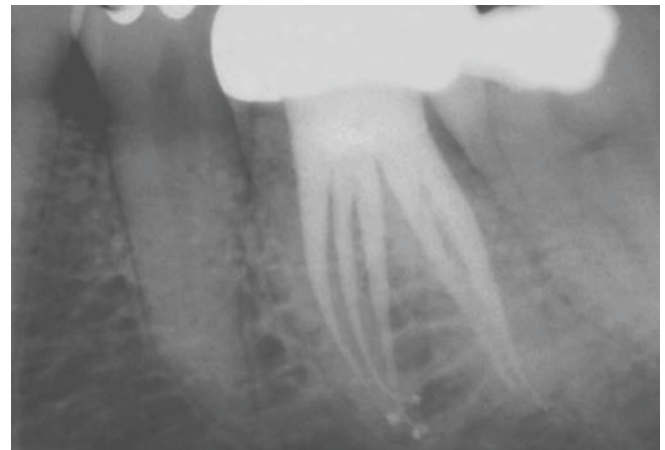


Figure 7b. The post-treatment film reveals 5 treated canals. Note the mid-medial was shaped more conservatively due to the external furcal-side concavity.

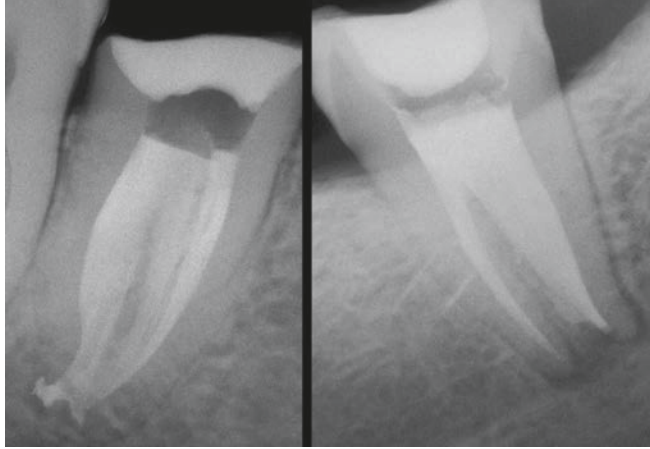

Figure 8. Left: A post-op image demonstrates an anatomical variation of an endodontically treated C-shaped molar. Right: This post-op image reveals a more classic C-shaped molar.

(www.ehuman.com). Knowledge and understanding for root canal system anatomy serve to influence and guide predictably successful endodontic treatment outcomes.

Radiographic Diagnostics: Even the best-angulated film is a two-dimensional representation of a three-dimensional object. As such, well-angulated periapical images should be taken in 3 different horizontal planes: straight-on, mesioblique, and distoblique. For example, another canal is suspected when a file or obturation material is radiographically positioned asymmetrically within the long axis of any given root. Importantly, Cone Beam Computed Tomography (CBCT) imaging is a major advancement in radiographic diagnostics, revealing anatomy and promoting the conservation of tooth structure during the access preparation.

Vision: Magnification plus lighting equals vision. Traditionally, magnification glasses, headlamps, and transilluminating devices have been used to enhance vision. However, the dental operating microscope has become the benchmark for unsurpassed lighting and magnification, which in turn, facilitates identifying orifices (**Figure 9**). Recently, Dr. Assad Mora, a Santa Barbara prosthodontist, developed a dual 3D camera system, termed MoraVision (www.moravision.com). This system affords a remarkable depth of field, where the clinician is able to see, at 8x, anterior and posterior teeth in focus, simultaneously.¹⁰ The MoraVision technology allows the operator to sit relaxed, move comfortably, and view 3D images in an interactive manner on a large 3D monitor.

Surgical Length Burs: Surgical length burs move the visually-obstructive head of the handpiece further away from the occlusal table. Long-length cutting instruments improve the line of sight along the shaft of the bur, promoting safety while encouraging the preservation of tooth structure when searching for canals.

Access Cavities: The finished access cavity should, more or less, enable the operator to look in a mouth-mirror into a furcated tooth and visualize all of the orifices without moving the

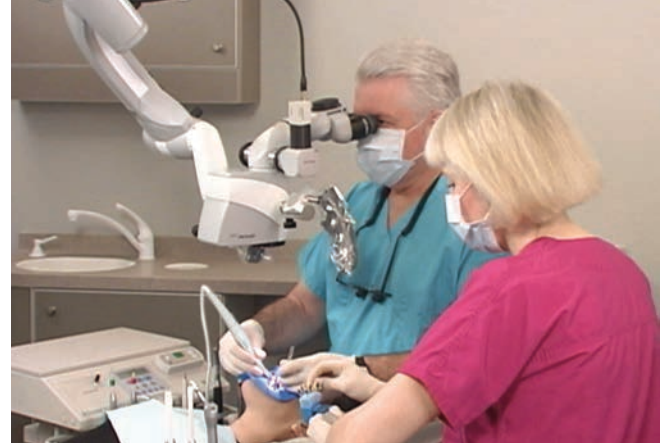

Figure 9. All phases of endodontic treatment are significantly improved when there is emphasis on and utilization of technologies that provide vision.

mirror. Importantly, axial walls should be flared, flattened, and finished to enhance vision, improve diagnostics, and provide straightline access to the orifice(s) (**Figures 1, 4, 7, 11**).

Piezoelectric Ultrasonics: The ultrasonic handpiece eliminates the bulky head of the conventional handpiece, which notoriously obstructs vision. The working ends of specific ultrasonic insert tips have abrasive surfaces to precisely sand away dentin and to chase and uncover hidden orifices (**Figure 10**). In combination, the microscope and ultrasonic insert tips have led to *microsonic* refinements in instrumentation.

Micro-Openers: Micro-openers are flexible, stainless steel hand files attached to an ergonomically designed offset handle. As an example, micro-openers provide unobstructed vision for initially penetrating and enlarging an offshoot that divides deep within a canal.

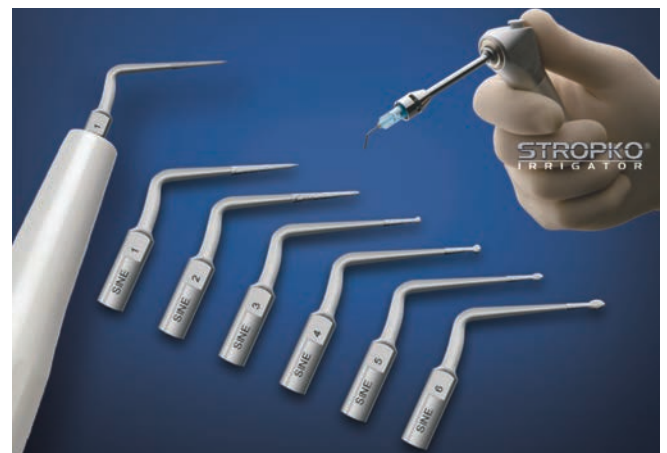

Figure 10. The ProUltra SINE ultrasonic instruments (Dentsply Sirona) feature unique tip configurations, abrasive coatings, and a contra-angle design for better visibility, while the Stropko Irrigator (www.stropko.com) collimates airlwater flow.

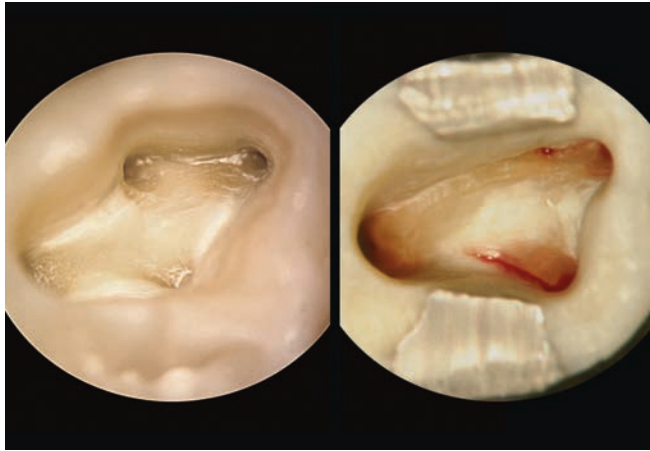


Figure 11. Left: This photograph demonstrates the access preparation and the “white line” connecting the MBI to a more mesially positioned MBII orifice. Right: This image shows initial access and the “red line” of blood emanating from the anatomical grooves off the MB and DB orifices.

Dyes: Methylene blue is a water-soluble dye that can be irrigated into a dry pulp chamber. The pulp chamber is subsequently rinsed with water, dried, and visualized. The dye is absorbed into orifices, fins, and isthmus areas. This technique serves to visually “map” hard-to-find orifices, fins and grooves, or certain coronal fractures.

Bubble Test: When NaOCl is flooded into the access cavity, it dissociates into Na⁺ and OCl⁻ ions and liberates free oxygen. The hypochlorite ion has a superior tissue-dissolving capacity. A positive “bubble” or “champagne” test signifies a reaction between OCl⁻ and pulpal tissue within a canal; or, bubbles signify a reaction between NaOCl and a residual viscous chelator that is oftentimes utilized in a canal when manually performing glide path procedures.

Transillumination: A fiber optic wand may be positioned cervically so that light is directed perpendicular to the long axis of a tooth. During transillumination, identifying an orifice is, at times, improved by turning off any overhead light source.

Explorer Pressure: The endodontic hand-held explorer should be strong, thin, and have a durable pointed tip. The JW 17 Micro-Explorer (*CliniMed*) provides a safe way to firmly sound or punch through a thin layer of secondary dentin in order to locate a hidden, receded, or more mineralized orifice of a canal.

White Line Test: When performing ultrasonic procedures without water in necrotic teeth, dentinal dust frequently settles into any available anatomical space. This dust can form a white dot within a hidden orifice or a white line within an anatomical fin, groove, or isthmus. This observation can provide a visible anatomical roadmap on the pulpal floor (**Figure 11**).

Red Line Test: In vital teeth, blood frequently emanates from an orifice, fin, or an isthmus area. Like a dye, blood serves to map and visually aid in the identification of the underlying anatomy. At times, a red dot is noted on the lateral aspect of

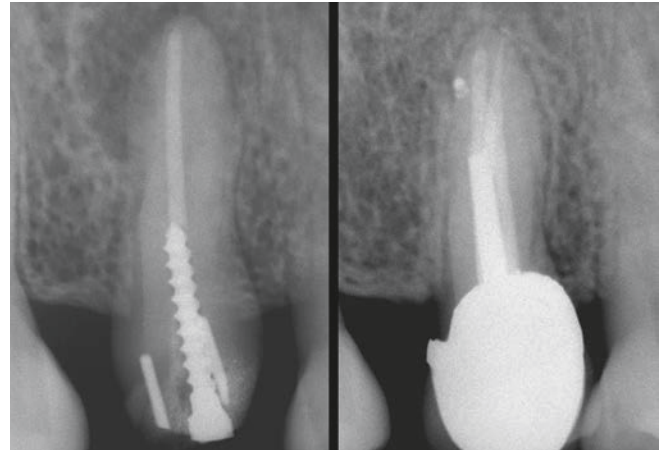


Figure 12. Left: A radiograph of an endodontically failing maxillary bicuspid. Note pins, a post, and that the obturation material is not centered within the root. Right: A 10-year recall radiograph shows excellent osseous repair, the importance of 3D endodontics, and a well-designed restorative.

a paper point, which may be associated with an offshoot or secondary canal within a canal (**Figure 11**).

Restorative Disassembly: Removing any given dental restoration provides direct visualization of the underlying tooth preparation. Coronal disassembly improves vision, orientation, and the predictability of safely identifying any given orifice (**Figures 1, 4**).

Perio-Probing: Circumferentially probing the sulcus of a tooth is another important strategy for locating canals. Intersulcular probing provides information as to the emergence profile of the clinical crown and the orientational alignment of the underlying root.

Symmetry: Any single root has a single canal when its orifice is positioned an equal distance from the external cavo surface of the root. In multi-rooted teeth, the orifices on the pulpal floor should exhibit symmetry between and/or among each other. The rules of symmetry will help to confirm that all the orifices and underlying canals have been identified (**Figure 12**).

Color: A dark, narrow line on the pulpal floor of a multi-rooted tooth provides a visual color-map that is helpful to locate a canal orifice. Visually, an orifice or fin will generally appear darker in color compared to the surrounding lighter-colored dentin (**Figures 4, 7**).

CLOSING COMMENTS

Whether you’re endodontically accessing a maxillary vs. a mandibular tooth, an anterior vs. a posterior tooth, a single vs. multi-rooted tooth, through a single-unit restorative vs. a bridge abutment, or performing initial treatment vs. endodontic retreatment, *if you can see it, you can do it*. The strategies outlined can help virtually any dentist perform more predictably successful treatment. However, if a missed canal is suspected, but cannot be identified, then an endodontic referral may be prudent to avoid a complication. Murphy’s Law of Committee states, “If more than one person is responsible for a miscalculation, no one will be at fault.” ▲

REFERENCES:

1. Hess W, Zürcher E: *The Anatomy of the Root Canals of the Teeth of the Permanent and Deciduous Dentitions*, New York: William Wood & Co, 1925.
2. Mangani F, Ruddle CJ: Endodontic treatment of a "very particular" maxillary central incisor, *J Endod* 20:11, pp. 560-561, 1994.
3. Kartal N, Ozcelik O, Cimilli H: Root canal morphology of maxillary premolars, *J Endod* 24:6, pp. 417-419, 1998.
4. Stropko JJ: Canal morphology of maxillary molars: clinical observations of canal configurations, *J Endod* 25:6, pp. 446-450, 1999.
5. Madeira MC, Hetem S: Incidence of bifurcations in mandibular incisors, *J Oral Surg* 36:4, 1973.
6. Vertucci FJ: Root canal morphology of mandibular premolars, *J Am Dent Assoc* 97:47, 1978.
7. Ruddle CJ: Microendodontic nonsurgical retreatment. In *Microscopes in Endodontics, Dental Clinics of North America*, Philadelphia : W.B. Saunders, 41:3, pp. 429-454, , July 1997.
8. De Moor RJ: The radix entomolaris in mandibular first molars; an endodontic challenge, *Int Endod J* 37:11, pp. 789-799, 2004.
9. Melton DC, Krall KV, Fuller MW: Anatomical and histological features of C-shaped canals in mandibular second molars, *J Endod* 17:8, 1991.
10. Buchanan LS: Inflection points in dental imaging, *Dent Today* 35:5, pp. 90-95, 2016.