

ENDODONTIC ACCESS PREPARATION

THE TOOLS FOR SUCCESS

by Clifford J. Ruddle, DDS

Endodontic performance is enhanced when clinicians thoughtfully view different horizontally-angulated, pre-operative radiographic images, visualize minimally invasive, yet complete, treatment, then use this mental picture to guide each procedural step.¹ There is an old expression... "Start with the end in mind." Before initiating the access preparation, think, visualize, and plan to more effectively execute a predictably successful result.

PRE-TREATMENT

Prior to endodontic treatment, an inter-disciplinary evaluation of pulpally involved teeth should be performed to ensure that optimal health is both possible and attainable. If the decision is to perform endodontic treatment, then it is advantageous, at times, to band and build up a tooth to facilitate subsequent procedures. Seriously broken-down teeth should be evaluated for periodontal crown lengthening procedures.² Crown lengthening facilitates endodontic isolation and enables the restorative dentist to achieve the ferrule effect and a healthy biological width.³ When indicated, crown lengthening serves to improve all phases of inter-disciplinary treatment.⁴ Endodontically, pre-treatment procedures elevate the potential for success by improving the predictability of each ensuing step.

Another endodontic pretreatment consideration is whether to access through or remove an existing prosthetic restoration. Clinicians typically access the pulp chamber through an existing

restoration if it is judged to be functionally designed, well fitting, and esthetically pleasing. If the restoration fails to meet the criteria for clinical excellence, then it is typically sacrificed. However, for a variety of reasons, it may be desirable to remove an existing restoration and preserve it intact. The safe and successful dislodgement of any given restorative requires knowledge in the preparation type, restorative design and strength, restorative material(s), cementing agent, and the selection and use of a few removal devices.⁵ Importantly, clinicians must consult with their patients and clearly communicate the risk versus benefit before commencing with removal procedures.

ISOLATION

Excellent vision in conjunction with complete isolation promotes predictably safe and successful endodontic treatment (*Figure 1*). Isolation accomplishes soft tissue retraction, protects the oral pharynx, and prevents salivary leakage. Fortunately, the vast majority of all teeth can be easily and quickly isolated for endodontic treatment in a one-step procedure. To accomplish this, an appropriately sized hole is punched at a pre-determined position through a rubber dam. The rubber dam may be stretched onto a non-metallic, polymer frame and then a pre-selected clamp is mounted onto the rubber dam. A polymer frame allows working films to be taken without concern for inadvertent metal superimposition over the region to be viewed.

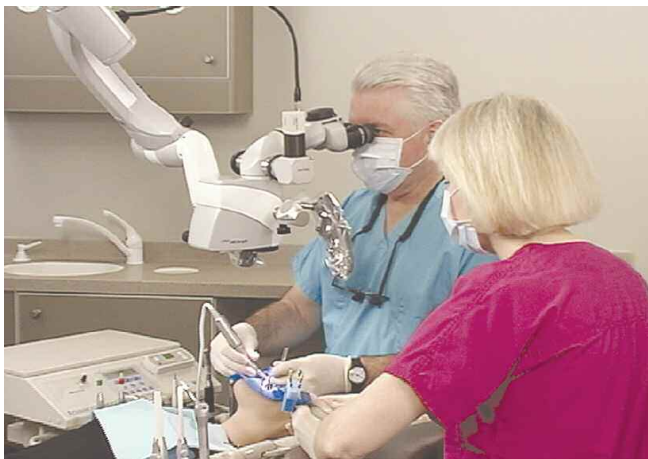

Figure 1a. This microscope provides unsurpassed ergonomics, superb visualization, and the opportunity to perform complete treatment.

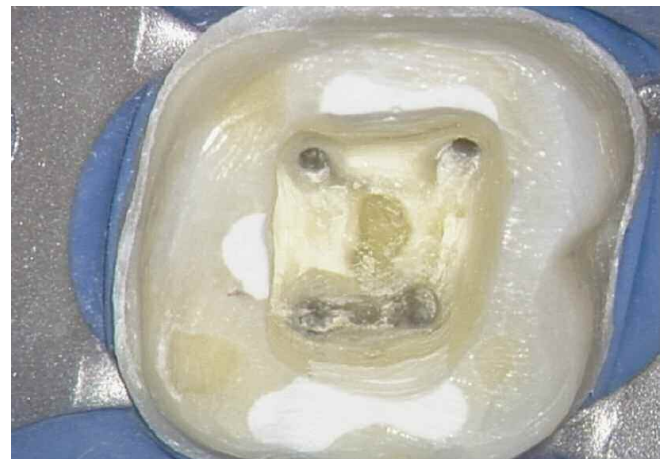

Figure 1b. A photo demonstrates isolation and straightline access to the orifices. Note the outline pattern, smooth axial walls, and five orifices.

The jaws of the Ivory #9 clamp will strongly grip virtually all bicuspid and anterior teeth, whereas the jaws of the Ivory #26 clamp will usually securely grasp most molar teeth. Although the Ivory #9 is considered to be a clamp for anterior teeth, it has distinct clinical advantages when isolating bicuspid teeth. This clamp will strongly grip the cervical region of bicuspid teeth and, fortuitously, its two bows are out of the way, providing unrestricted access to the isolated tooth to be treated. The forceps guide the jaws of the clamp over the crown and are released so they securely engage the tooth and do not impinge on soft tissue. An explorer is oftentimes used to lift and release the rubber dam off the facial and lingual wings of the clamp.

Dental floss may be used to work the rubber dam between the contact points and carry it gingivally so as to establish a dry working field. On occasion, even when the dam has been well placed, there may be a nuisance contamination leak. As such, caulking materials, such as OraSeal (*Ultradent; South Jordan, UT*), are available to secure a fluid-tight treatment environment. Infrequently, but on

occasion, it may be useful to initiate an endodontic access cavity without a rubber dam to improve orientation. This may be considered when encountering heavily restored teeth, significant calcification within the pulp chamber, or when the clinical crown is not aligned with the underlying root (*Figure 2*).

ACCESS OBJECTIVES

The access preparation is an essential element for successful endodontics.⁶ Preparing the endodontic access cavity is a critical step in a series of procedures that potentially leads to the three-dimensional obturation of the root canal system (*Figure 3*). Access cavities should be cut so the pulpal roof, including all overlying dentin, is removed. The size of the access cavity is primarily influenced by the anatomical position of the orifice(s). The axial walls are extended laterally such that the orifice(s) is just within this outline form. When required, access preparations are further expanded to eliminate any other restrictive interference that could compromise any aspect of ensuing treatment.⁷

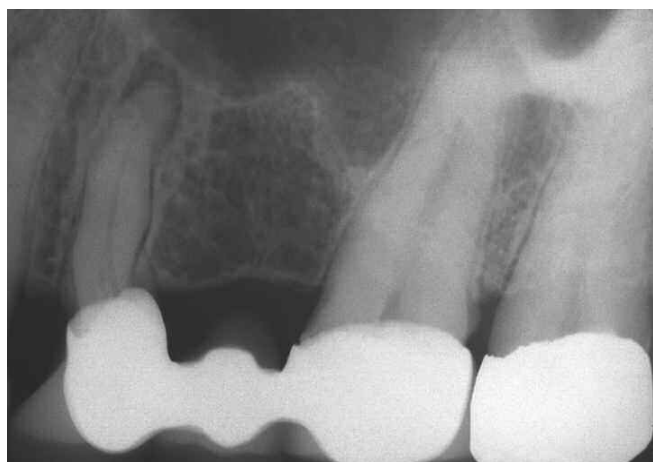

Figure 2a. This anterior bridge abutment is endodontically involved. Note the inclination of the metal/porcelain restorative crown relative to the root.

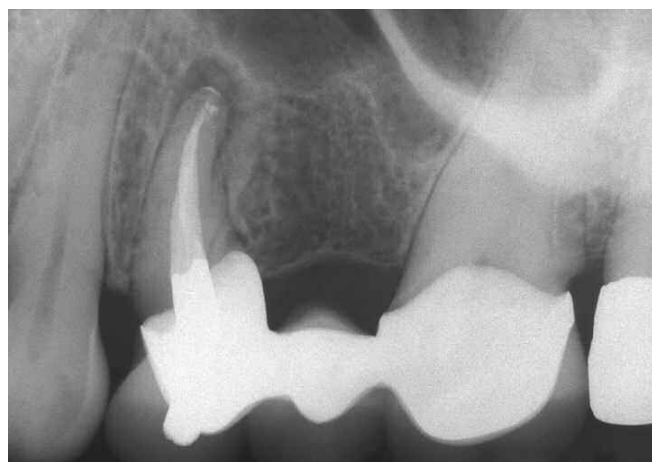

Figure 2b. A post-treatment radiograph demonstrates complete endodontics. Note the pathway of the access through the crown to the underlying root canal system.

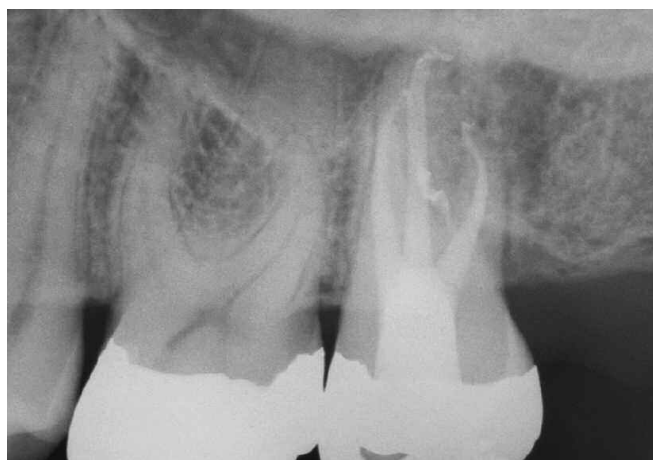


Figure 3a. This post-treatment film demonstrates straightline access, apical curvature and recurvature of the P and DB systems, and a treated furcal canal.

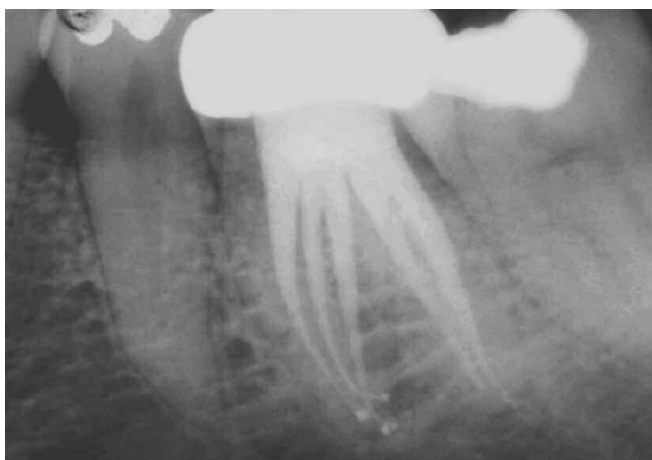

Figure 3b. This post-treatment film illustrates straightline access and that three mesial and two distal systems were identified, shaped, and filled.

Endodontic access cavities should parallel the principle of restorative dentistry. Dentists performing prosthetic dentistry readily appreciate the importance of being able to withdraw a wax pattern from a stone or copper dye without distorting the wax. Endodontically, access objectives are confirmed when all the orifices of a furcated tooth can be visualized without moving the mouth mirror. Cleaning and shaping potentials are dramatically improved when instruments conveniently pass through the occlusal opening, effortlessly slide down smooth axial walls, and are easily inserted into a preflared orifice (*Figure 4*). Spacious access cavities are an opening for canal preparation.⁸⁻¹⁰ Properly performed, the finished preparation should provide both coronal and radicular straightline access.

ARMAMENTARIUM FOR ACCESS

The access armamentarium should be simple, yet sufficiently versatile, to achieve the preparation goals. Every dentist

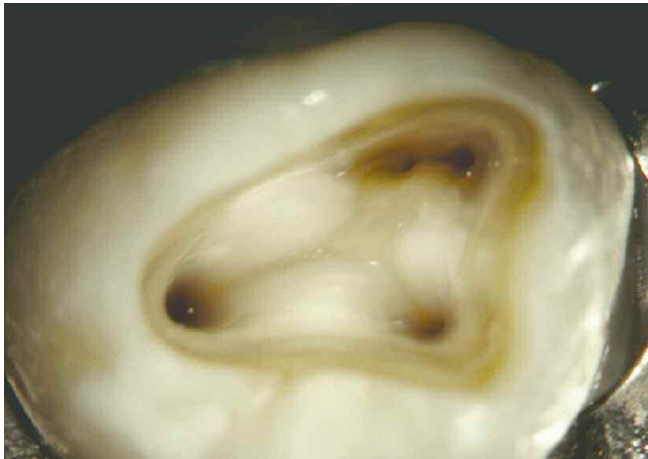

Figure 4. This photo demonstrates straightline access. The axial walls are finished and the preflared orifices are just within this outline pattern.




Figure 6a. #2 and #4 diamond round burs

who performs endodontic procedures has a preferred set of burs that are used for any given access procedure. Fortunately, only two, three, or four rotary cutting burs are typically required to create an optimal access cavity. Although it is normal for any given clinician to have a specific preference, generally most dentists can agree on a core set of burs. The following will provide a brief description of the Endo Access Kit (*Dentsply Tulsa Dental Specialties; Tulsa, Oklahoma*) that may be used to initiate, progressively open, and completely finish any access cavity within any tooth in the mouth (*Figure 5*).

- *Diamond Round Bur:* The #2 and #4 diamond round burs, in conjunction with water, are utilized to brush-cut away tooth-colored restoratives and to create a window through materials such as porcelain (*Figure 6a*). A #2 diamond round bur is appropriately sized for bicuspid and anterior teeth, whereas the #4 diamond round bur is generally the right size for molar teeth.

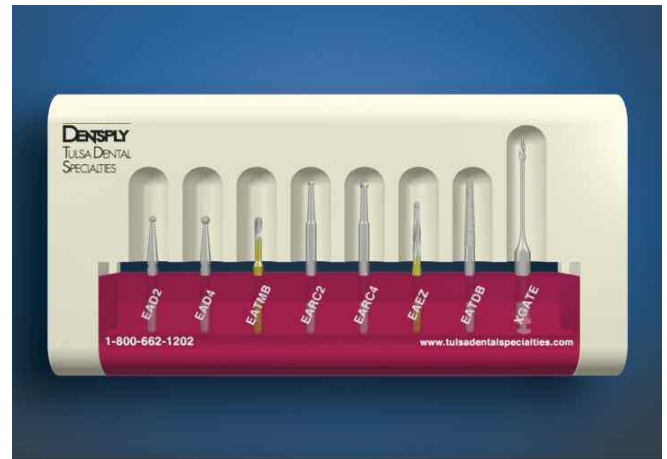

Figure 5. The convenient Endo Access Kit provides the fewest burs to initiate, progressively expand, and completely finish any access preparation.

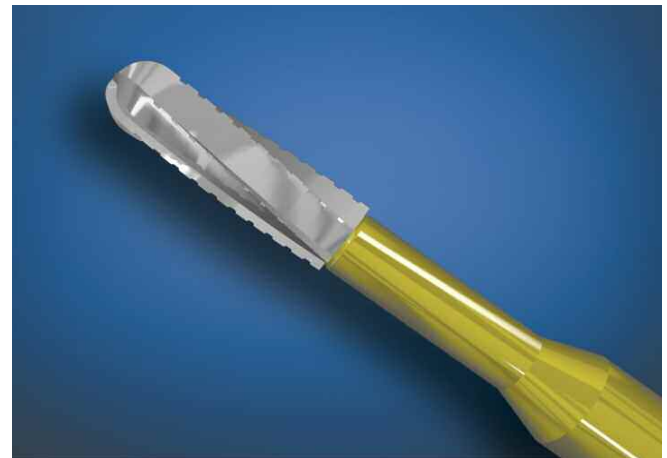

Figure 6b. Transmetal bur

- **Transmetal Bur:** The transmetal bur is specifically designed for cutting any type of metal (*Figure 6b*). This bur has a saw-tooth blade configuration, which provides efficiency while reducing unwanted vibration, especially important when entering pulpitic or so-called "hot teeth."
- **Carbide Round Burs:** The #2 and #4 surgical length carbide round burs provide extended reach and improved vision during the entry into the pulp chamber (*Figure 6c*). Fortuitously, longer shank burs move the bulky head of the handpiece further away from the occlusal table, giving the clinician a line of sight along the shaft of the bur. These burs are used to remove variously encountered restorative materials and dentin, including the overlying roof of the pulp chamber. Again, the #2 round bur is appropriately sized for bicuspid and anterior teeth, whereas the #4 round bur is sized best for molar teeth.
- **Endo Z Bur:** The Endo Z bur is a tapered and safe-ended carbide bur (*Figure 6d*). This bur is popular in that its non-cutting end can be safely placed directly on the pulpal

floor without a risk of perforation. The Endo Z bur's lateral cutting edges are used to flare, flatten, and refine the internal axial walls.

- **Tapered Diamond Bur:** A surgical length tapered diamond bur may be utilized at high speeds to flare, flatten, and finish the axial walls of the pulp chamber (*Figure 6e*). A surgical length tapered diamond bur is utilized to expand the access preparation and to blend the axial walls so the orifice(s) is just within this outline pattern. Strategically, a surgical length, tapered, and end-cutting diamond bur can be safely used at slow speeds of 500-750 rpm to safely, selectively, and precisely sand away dentin, track along grooves in search of hidden orifices, or when space is available, to remove certain triangles of dentin.
- **X-Gates:** One X-Gates is comprised of four Gates Glidden (GG) drills. Specifically, the heads of the GG 1-4 burs are sequentially stacked on the active portion of a single X-Gates to create a funnel-shaped form (*Figure 6f*). The X-Gates is rotated at a slow speed of 500-750 rpm and is



Figure 6c. #2 and #4 surgical length carbide round burs



Figure 6d. Endo Z bur



Figure 6e. Surgical length tapered diamond bur

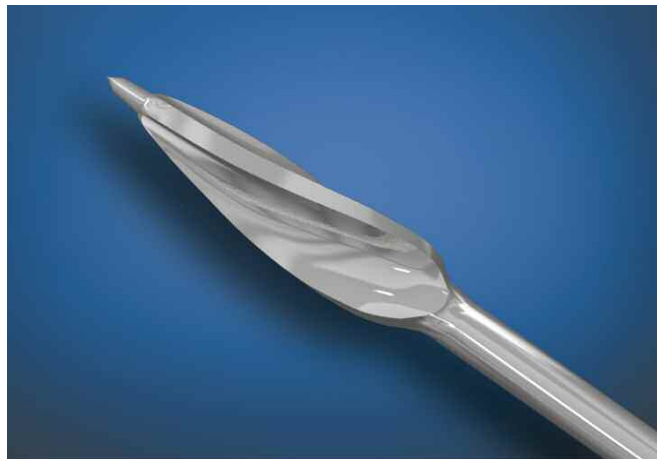

Figure 6f. X-Gates bur

used like a brush to cut dentin with its lateral surfaces or belly on the outstroke. The X-Gates may be used for three strategic purposes: (1) to initially open, flare, and smoothly blend the canal orifice(s) to the axial walls, (2) to remove internal triangles of dentin, and importantly, (3) to intentionally relocate the coronal-most portion of a canal away from furcal danger. Together, the X-Gates and surgical length diamond bur are the burs of choice for finishing the preparation and providing easy access to the underlying root canal space.

- **Vision:** Lighting and magnification equal vision. Magnification glasses, headlamps, fiber optic trans-illuminating devices, and dental operating microscopes (DOM) contribute to better vision. The DOM affords superior vision, while providing options in magnification and coaxial lighting. Specifically, the line of Zeiss operating microscopes (*Zeiss Meditec; Dublin, CA*) provides unique features exclusive to dentistry (*Figure 1a*).
- **Piezoelectric Ultrasonic Generators:** Piezoelectric ultrasonic energy is a strategic technology and plays an ever-increasing role when performing hygiene, restorative dentistry, and nonsurgical endodontic procedures. Additionally, piezoelectric ultrasonic energy is useful when performing certain maxillofacial, periodontal, and

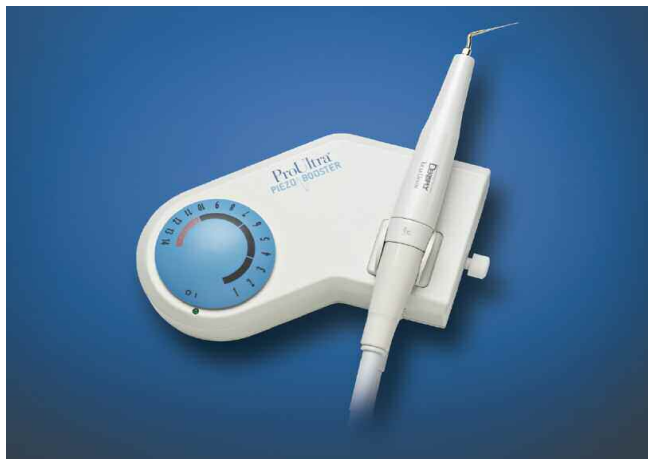

Figure 7a. The P5 ultrasonic generator offers many advantages when performing a variety of endodontic procedures.

endodontic surgical procedures. Importantly, ultrasonically driven procedures remove the bulky head of a traditional handpiece, providing an unsurpassed line of sight into the operating field. The P-5 ultrasonic generator (*Dentsply Tulsa Dental Specialties; Tulsa Oklahoma*) provides advantages when performing conventional and nonsurgical endodontic retreatment (*Figure 7a*). This generator has a broad energy range, provides precise incremental power, and electronically locks in and regulates tip movement.

- **Ultrasonic Instruments:** Ultrasonic instrumentation is playing an increasingly larger role in the field of endodontics. Ultrasonic instruments are available in varying lengths, diameters, tapers, and various abrasive cutting surfaces. Furthermore, instruments are offered in a variety of tip configurations and with or without water port delivery. In general, the specific instrument selected is based on the clinical task to be performed (*Figure 7b*). In the context of this article, ultrasonic instrumentation is used to eliminate pulp stones, trough along grooves to uncover hidden orifices, and chase calcified canals. Importantly, ultrasonic instrumentation procedures are utilized to refine and finish the access preparation. Microscopes, in combination with ultrasonic instruments are driving an increasing number of "microsonic" techniques.




Figure 7b. The ProUltra ENDO 1-5 ultrasonic instruments provide an abrasive surface with a zirconium nitride coating to improve efficiency, precision and performance.

ACCESS TECHNIQUES

Having knowledge of the range of anatomical variation associated with the various groups of teeth helps the clinician to more successfully access and treat virtually any endodontically involved tooth.¹¹ From experience, it is best to initially prepare the size of the access window about 80% of what the final outline form will ultimately expand and become. Initially preparing a generous opening improves vision as the preparation moves deeper into the tooth. Once the pulpal roof has been removed, then the position of the orifice(s) may be identified. With anatomical orientation, the position of the axial walls may be adjusted, and the access preparation fully expanded and finished accordingly.¹²

To initiate treatment, the appropriate bur is selected based on the material comprising the clinical crown. When the material is a tooth-colored restorative, such as porcelain, the clinician may select either a #2 or #4 diamond round bur, depending on the specific tooth to be treated (*Figure 8a*). When accessing

through metal restoratives, the clinician may select the transmetal bur to improve efficiency while reducing unwanted vibrations (*Figure 8b*). Depending on the tooth to be treated, the clinician may select either the #2 or #4 surgical length carbide round bur to provide extended reach and improved vision. These burs are used primarily to eliminate cements, remove composites, and cut dentin. Like a painter painting a canvas, the clinician moves the handpiece utilizing a light brush-cutting motion. The bur is swept mesial to distal and facial to lingual, as the access preparation is extended toward the roof overlying the pulp chamber. A light brushing motion with a new sharp bur reduces friction and related heat and affords more control when progressively carrying the access preparation pulpally. From a patient's perspective, brush-cutting versus drilling dentin promotes peaceful endodontics, especially when accessing pulpitic teeth. The access cavity is continued until the pulpal roof is penetrated. Upon entry, an appropriately sized surgical length carbide round bur is placed inside the chamber and is repetitively dragged occlusally until the entire pulpal roof has been removed (*Figure 8c*).

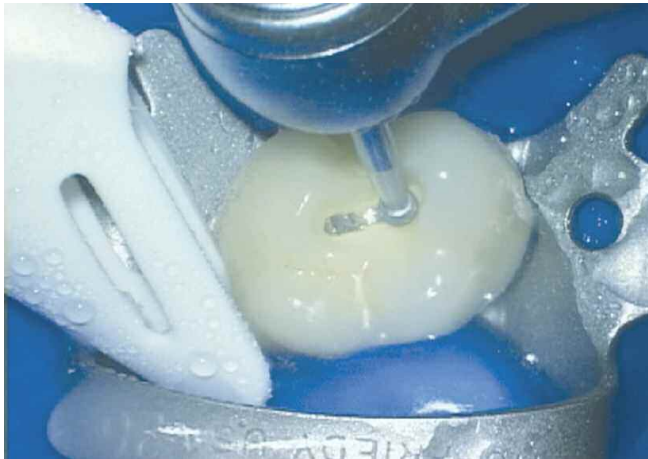

Figure 8a. In this photo, a diamond round bur in conjunction with a water coolant is utilized to initiate access through a porcelain fused to metal crown in this example.

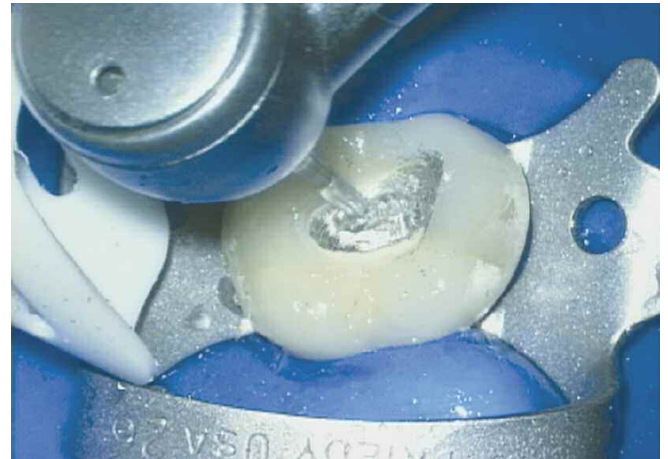

Figure 8b. The saw-tooth blade configuration of the transmetal bur reduces vibration and improves efficiency when cutting a window through a metal restorative.

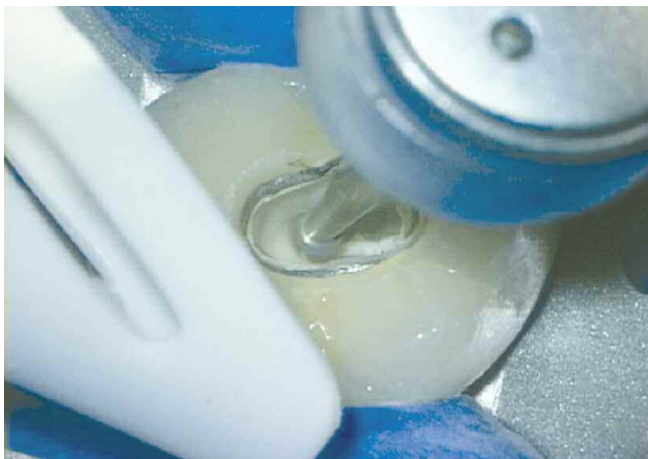

Figure 8c. A surgical length carbide round bur provides a line-of-site for progressively extending the access preparation pulpally and de-roofing the chamber.

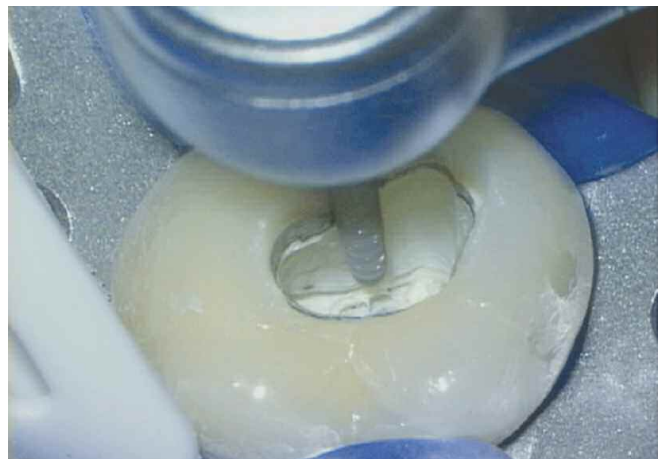

Figure 8d. A surgical length tapered diamond bur provides continuous vision when smoothing, flaring, and finishing the axial walls of the access preparation.

After completely de-roofing the pulp chamber and identifying the orifice(s), the Endo Z bur or surgical length tapered diamond bur may be used to flare the axial walls so they diverge from the pulpal floor towards the occlusal surface (*Figure 8d*). Smooth, flat, and finished axial walls improve the refraction of light and, hence, vision. The Endo Z bur or a surgical length tapered diamond bur serve to create straightline access to each orifice. When radicular space is available, an explorer may be placed into an orifice to determine the entry angle of any given canal relative to the long axis of the tooth. When radicular space is more restrictive, a small-sized hand file can generally be inserted into the coronal-most aspect of a canal to judge the entry angle of the canal relative to the long axis of the tooth. Placing a small-sized hand file will disclose the angle and exact orientation with which to hold the slow speed handpiece and related X-Gates rotary cutting instrument.

The access cavity can oftentimes be finished with a single stainless steel X-Gates. This procedure serves to preflared the orifice, establish a reproducible opening to any canal, and facilitate subsequent instrumentation. In the instance

where the orifice is calcified, a few small-sized hand files may be used in the coronal aspect of the canal to create sufficient space to accommodate the head of the X-Gates. Research has shown that a single X-Gates can be used at a *low speed* and with a *brushing action* to safely and selectively cut dentin on the outstroke. This method of preflaring an orifice will produce a final preparation that is centered within the circumferential dimensions of the root (*Figure 9*). On the contrary, simply spinning a rotary NiTi file inside a canal invites two problems. First, a rotating file will produce an ever-expanding round hole within a canal that is not necessarily centered within the cross-sectional anatomy of any given root.^{5,13} Preparations that are not centered within the root predispose to root thinning, radicular fractures, and strip perforations. The second problem with merely spinning a NiTi rotary file is it creates of an overly simplistic round hole within a canal whose cross-sectional anatomy is frequently irregularly shaped. Anatomical μ CT studies show that canals commonly exhibit cross-sectional configurations that are ovoid, are figure eight-shaped, or display fins off their rounder portions.

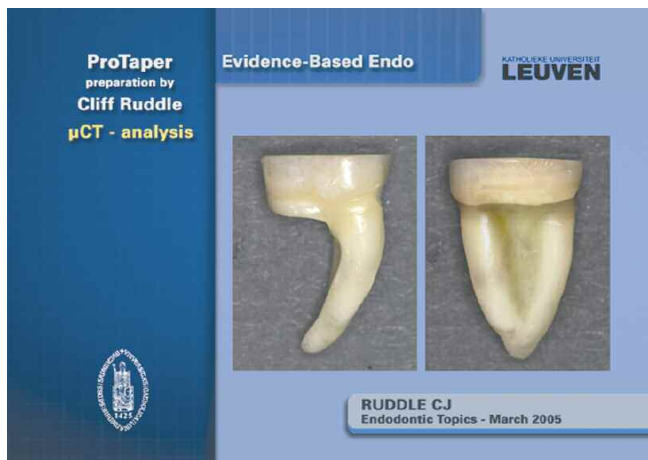

Figure 9a. A μ CT image of a mandibular molar demonstrates the distal root has been removed and that the mesial root has a furcal side concavity.

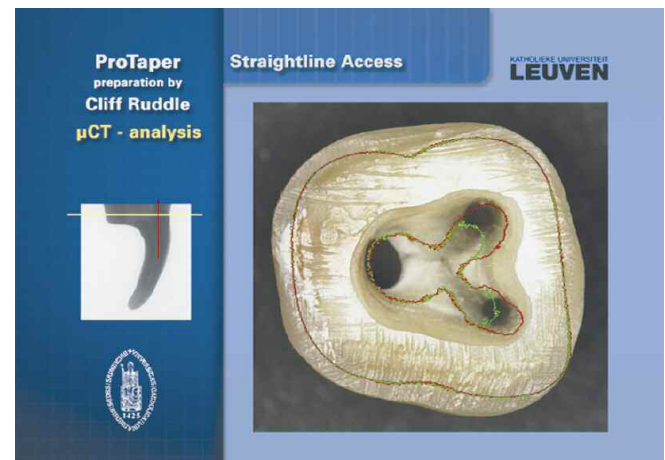

Figure 9b. The green outline pattern seen in this μ CT image demonstrates the original anatomical position of the orifices. The red outline pattern shows that the orifices have been intentionally relocated away from furcal danger.

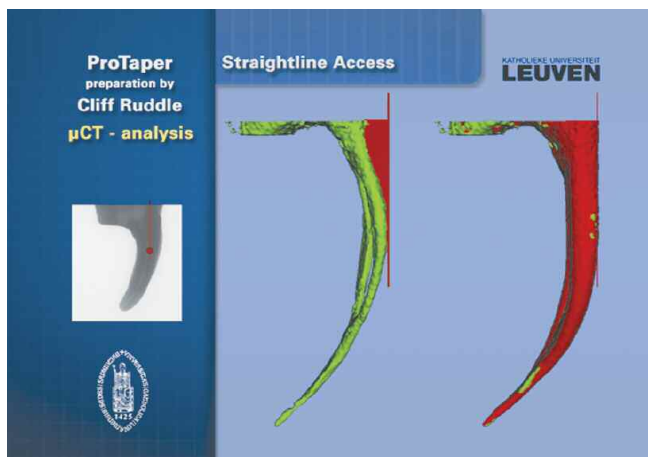
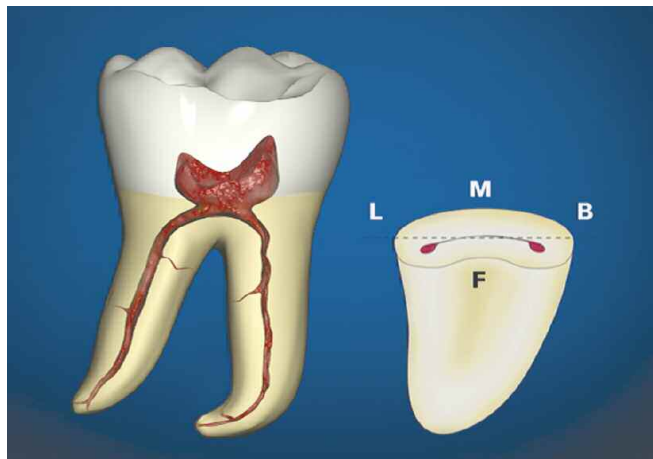


Figure 9c. A μ CT image shows before (green) and after (red) shaping procedures. The red triangle of dentin (left image) was removed with the X-Gates (right image).

(Figures 9a-9c represent clinical work performed by Dr. Cliff Ruddle, and the μ CT images courtesy of Dr. Lars Bergmans and BIOMAT Research Cluster, Catholic University, Leuven, Belgium).

Excluding teeth that exhibit calcification within the pulp chamber, most orifices can typically accommodate the head or working portion of the X-Gates. As a guideline, the non-rotating, cutting portion is initially placed just within the orifice. Upon activation, the head of the handpiece is moved in a circular motion, which serves to open, expand, and flare any given orifice. Once the orifice has been preflared, the lateral cutting surface or the belly of the X-Gates may be used to intentionally relocate the coronal-most aspect of a canal away from furcal danger, remove an internal triangle of dentin, and to blend the orifice to the adjacent axial wall. A preflared orifice produces a smooth, flowing funnel to easily facilitate the subsequent placement of small-sized hand files. In smaller diameter canals, typically associated with the buccal roots of maxillary molars or the mesial roots of mandibular molars, limit the depth of insertion so that the flame-shaped active portion of the X-Gates is no more than one head length below the orifice.

Fortuitously, utilizing the X-Gates with a brushing action allows clinicians to more fully address root canal cross-sectional configurations that are frequently irregularly shaped anatomically. It is perfectly normal to break the shaft of an X-Gates when it is used correctly and deliberately like a brush.



Breaking the shaft of an X-Gates is clinically a non-issue, as the active portion is completely loose in the canal during use.

Preflaring and intentionally relocating the coronal one-third of a canal is a strategic decision. Cross-sections through the coronal one-third of furcated roots reveal that canals are not typically centered anatomically within their roots, but rather are generally displaced toward the furcal-side concavities (*Figure 10*). Clinicians can observe the handle position of the smaller-sized instruments to see if they are upright and parallel to the long axis of the tooth, or if they are skewed off-axis. When the handle of the file is upright, or ON the long axis of the tooth, then the clinician is able to confirm both coronal and radicular straightline access. However, when the handle of the initial instrument is OFF the long axis of the tooth, then recognize the triangle of dentin must be removed to upright the file handle and position it ON axis (*Figure 11*).⁷

Scouter files confirm the presence or absence of straightline coronal and radicular access. Complete straightline endodontic access influences and simplifies all subsequent instrumentation procedures while virtually eliminating many cleaning and shaping frustrations.⁵ As has been previously mentioned, following the

Figure 10. A cross-section through the mesial root illustrates the orifices are not centered and are generally positioned closer toward the furcal side concavity.

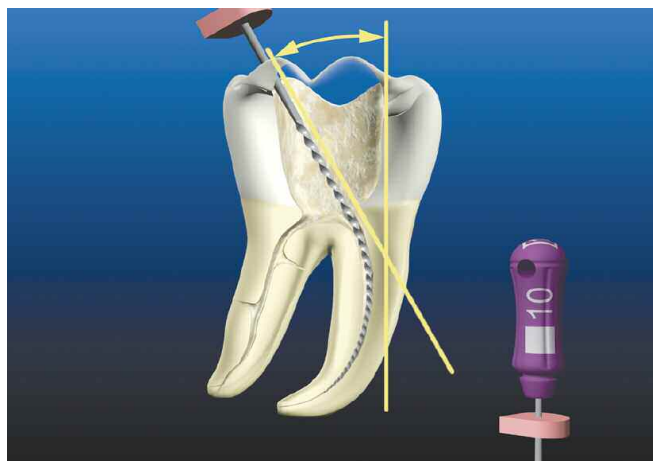

Figure 11a. In furcated teeth, when a small-sized file is initially inserted into the canal, its handle is frequently OFF axis due to an internal triangle of dentin.

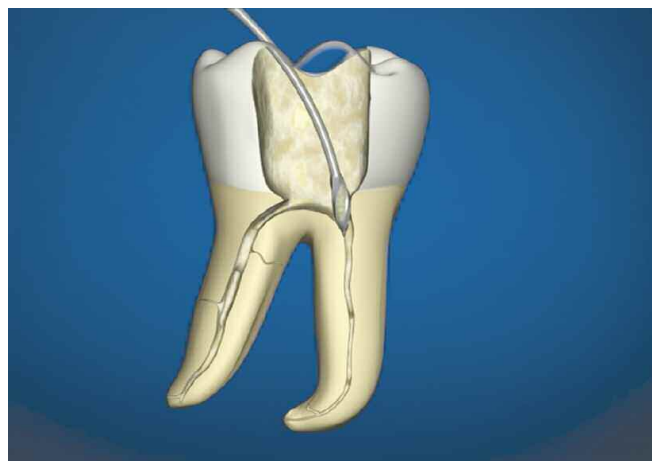


Figure 11b. The shaft of the X-Gates is arced so its head will selectively cut, remove internal triangles of dentin, and intentionally move the canal away from furcal danger.

use of the X-Gates, the access cavity is almost routinely adjusted and subtly refined with a surgical length tapered diamond bur to fulfill the mechanical objectives for straightline access and to promote all ensuing treatment steps. The access preparation should be thought of as a progressive procedure that frequently requires adjustment during canal preparation procedures.

CONCLUSION

This article has described concepts, strategies, and techniques for creating predictably successful endodontic access preparations. It could be said endodontic performance may be thought of as a game, and as such, can be played at various levels of skill, producing a range of results. The endodontic access preparation influences all ensuing treatment steps and provides the opening for shaping canals, cleaning root canal systems, and three-dimensional obturation. Visualizing and executing great play moves each clinician toward mastery and winning the inner game of endodontics. ▲

REFERENCES

1. Burns RC, Herbranson EJ: Ch. 7: Tooth morphology and cavity preparation. *Pathways of the Pulp*, 7th ed., Cohen and Burns, Mosby, St. Louis, 1998.
2. Nevins M, Mellonig JT (ed.): *Periodontal Therapy, Clinical Approaches and Evidence of Success*, Quintessence Publishing Company, Chicago, 1998.
3. Lenchner NH: Restoring endodontically treated teeth: ferrule effect and biologic width, *Pract Periodont Aesth Dent* 1:19, 1989.
4. Sorensen JA, Engelman MJ: Ferrule design and fracture resistance of endodontically treated teeth, *J Prosthet Dent* 63:529, 1990.
5. Ruddle CJ: Ch. 25, Nonsurgical endodontic retreatment. In *Pathways of the Pulp*, 8th ed., Cohen S, Burns RC, eds., St. Louis: Mosby, pp. 875-929, 2002.
6. Levin H: Access cavities. *Dent Clin North Am* 11:701, November, 1967.
7. Ruddle CJ: Ch. 8, Cleaning and shaping root canal systems. In *Pathways of the Pulp*, 8th ed., Cohen S, Burns RC, eds. St. Louis: Mosby, pp. 231-291, 2002.
8. Machtou P: Ch. 8, La cavité d'accès. In *Endodontie - guide clinique*, Pierre Machtou, ed., Paris: Editions CdP, pp. 125-137, 1993.
9. Ruddle CJ: The protaper technique. *Endodontic Topics* 10: 187-190, 2005.
10. Schilder H: Cleaning and shaping the root canal system. *Dent Clin North Am* 18(2):269, 1974.
11. Brown WP, Herbranson EJ: Brown and Herbranson Imaging, Portola Valley, CA: www.toothatlas.com, 2005.
12. Ruddle CJ: *Ruddle on Clean•Shape•Pack*, 2-part video series/DVD. Studio 2050, producer, Santa Barbara, California: Advanced Endodontics, 2002.
13. Ruddle CJ: *Ruddle on Retreatment*, 4-part DVD series. James Lowe Productions/Studio 2050, producers, Santa Barbara, California: Advanced Endodontics, 2004.