

ENDODONTICS 101

BACK TO BASICS

by Clifford J. Ruddle, DDS

Much has changed in global endodontics over the past 40 years and a great deal of this change has been driven by the relentless introduction of new technology. Virtually all of these technologically driven innovations have been intended to improve the treatment of root canal systems (*Figure 1*). Yet, with all the emphasis on technology, it is interesting to note that

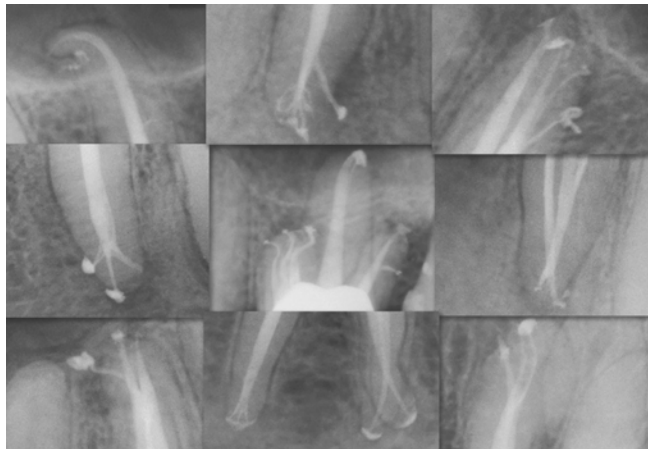


Figure 1. This collage of post-treatment endodontic images demonstrates canal preparation, 3D disinfection, and filling root canal systems.

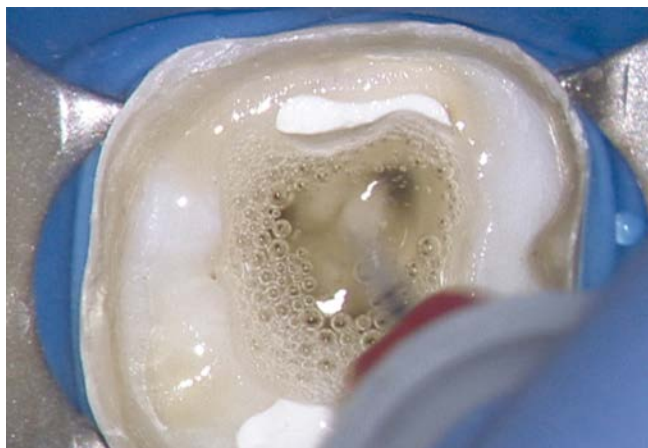

Figure 2a. This clinical image shows the EndoActivator (Dentsply Sirona) initiating the exchange of a reagent.

endodontic success rates today remain virtually the same as reported over previous decades. This raises the question, is predictably successful endodontic treatment more dependent on technology or proven clinical concepts?

It is a fact that technology has vaulted clinical endodontics toward ever-increasing possibility. For example, the dental operating microscope was introduced into clinical dentistry in the mid-1970s. In 1988, diagnostic imaging took a leap forward with the advent of CBCT in dentistry. During this same decade, ultrasonically-driven insert tips were refined to better perform micro-instrumentation techniques. In the early 1990s, NiTi files emerged and sparked a mechanical revolution in preparing canals; and by the late 1990s, endodontics witnessed a new bio-compatible material, termed mineral trioxide aggregate or MTA.

In recent years, 3D disinfection methods have evolved that better exchange reagents into all aspects of the endodontic anatomy (*Figure 2*). Bioactive obturation materials are emerging in the marketplace and hold promise to ignite a new era of regenerative endodontics. There is also growing emphasis on a comprehensive root-to-crown treatment approach; this is inspiring a new generation of tooth-colored restorative materials for internally sealing the pulp chamber and access cavity, in the instance when endodontics is performed through an




Figure 2b. SEM images show evidence that the EndoActivator System can 3D clean root canal systems (courtesy of Dr. Grégory Caron; Paris, France).

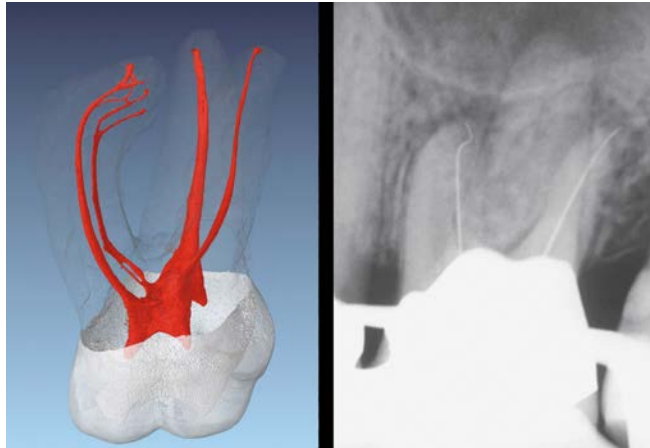


Figure 3a. Left: A μ CT image of a maxillary molar demonstrates challenging root canal system anatomy (Courtesy of Dr. Frank Paque; Zurich, Switzerland). Right: A working film of a maxillary first molar demonstrates size 10 files at the radiographic terminus (RT). Note the MB1 apical one-third recurvature.

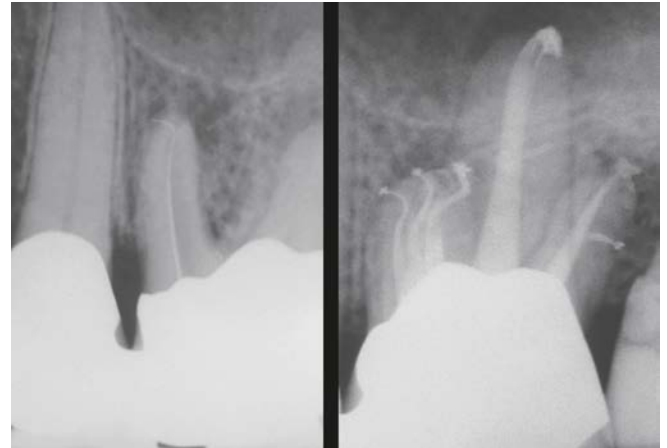

Figure 3b Left: This working film shows a size 10 file at the RT. Note that the MB3 system has an abrupt apical hook. Right: The post-op demonstrates how working length, patency, and securing canals influences treating root canal systems.

existing, well-designed, and esthetically pleasing restoration. All of these technologies, each in their own way, have gained traction and have served to launch clinical endodontics into a new future.

However, with all the benefits of technology, the question remains what's frequently missing that, if discovered, could redirect clinical endodontics on a new trajectory toward unparalleled success? What if dentists could more predictably negotiate any given canal to its terminal extent? Developing a smooth reproducible glide path to length, or securing a canal, can be a tricky challenge, but it is the essence of glide path management (GPM). GPM requires a knowledge, respect, and appreciation for endodontic anatomy, as well as a mechanical strategy, desire, and determination (**Figure 3a**).

Importantly, GPM influences shaping canals, which in turn, affects 3D cleaning, and filling root canal system (**Figure 3b**).

This article will briefly review the anatomical and clinical considerations that frequently pose challenges when performing endodontic treatment within the apical one-third of any given root (**Figure 4**). The focus of this article will be on presenting a logical clinical rationale for working length that will more predictably promote the mechanical and biological objectives for preparing canals. The purpose of this article is to emphasize how the words we use shape our thoughts and serve to guide our clinical actions. As we will see, utilizing proven clinical concepts, as well as relevant and best technology, are essential to guide each case toward a successful conclusion.

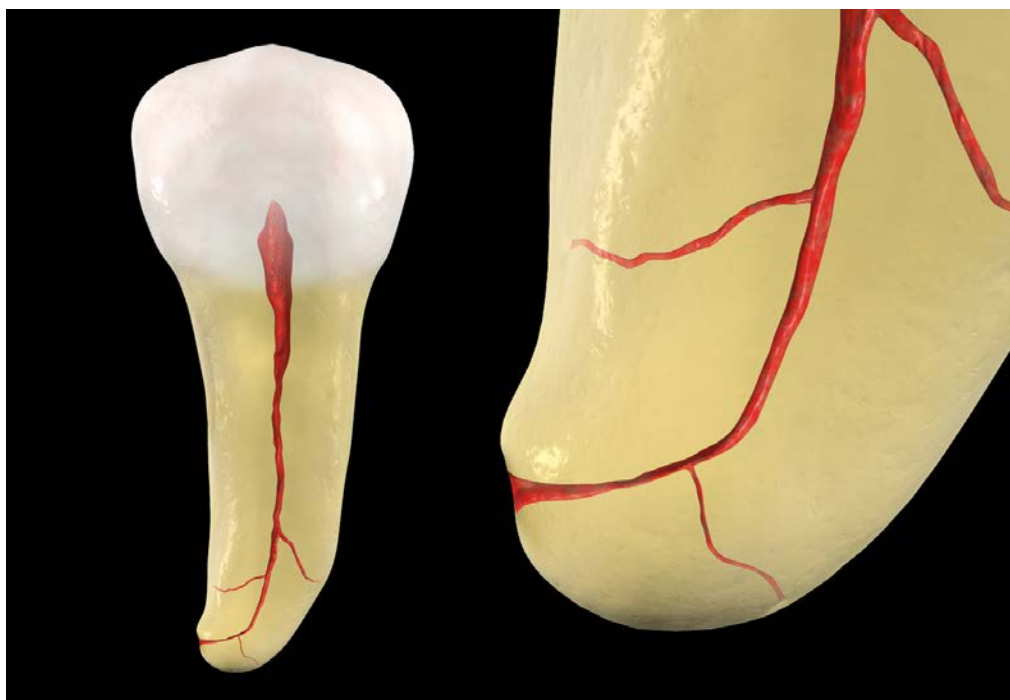


Figure 4. An illustration of a mandibular bicuspid reveals that the terminal extent of this canal exhibits considerable curvature and reverse apical architecture.

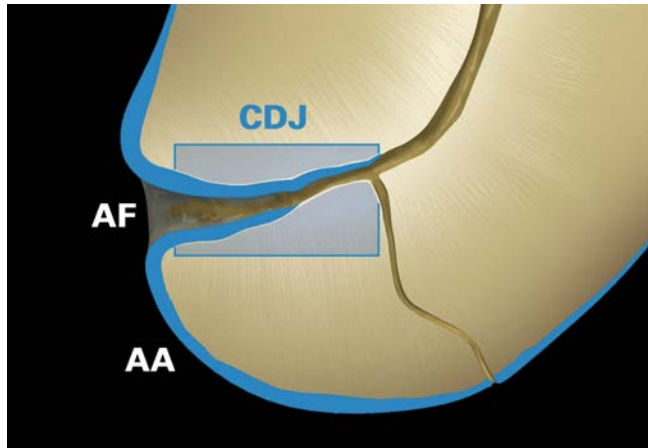


Figure 5. Note the anatomical foramen (AF), the anatomical apex (AA), and that the cementodentinal junction (CDJ) is an uneven zone.

ANATOMICAL AND CLINICAL CONSIDERATIONS

The anatomical view a technician can directly visualize through a microscope is very different from what a dentist can interpret using diagnostic radiographic images, electronic apex locators, and experience. For example, histologists use the terms *apical foramen* (AF) and *anatomical apex* (AA), which can be directly visualized on the external root surface (Figure 5). However, clinicians oftentimes use the term *radiographic terminus* (RT) to denote when the tip of a file coincides with the edge of the root, and the term *radiographic apex* (RA) to describe the most apical, dome-shaped part of the root (Figure 6). The terms RT and RA are incorrectly used interchangeably, even though these 2 locations commonly differ on the external root surface.¹

Another histological landmark that is clinically misunderstood is the cementodentinal junction (CDJ). The CDJ is formed when cementum on the external root surface invaginates through the apical foramen, extends in a coronal direction anywhere from a few microns to several millimeters, and meets dentin within the internal walls of the canal.¹⁻² The CDJ, oftentimes

referred to as the constriction, continues to be advocated as the ideal histological landmark to terminate endodontic treatment. Yet clinically, the CDJ is an imaginary landmark, as it is a scalloped or uneven zone that varies infinitely from tooth to tooth, from root to root on the same tooth, and from one wall to the opposite wall within the same root canal (Figure 5).¹⁻³

Even with advancements in electronic apex locators, it is still clinically problematic to attempt to vertically prepare a canal to the CDJ. It is ill-advised to work short because dentine mud, the by-product of instrumentation, accumulates and can potentially contribute to countless iatrogenic events.⁴ Further, the most terminal aspect of any given canal oftentimes variably widens from the CDJ toward the foramen that opens on the external root surface. This uneven zone of reverse apical architecture contains pulp tissue (Figure 6). For many, the clinical dilemma remains, do we manage vital vs. necrotic pulpally involved teeth differently, should vital tissue be preserved or eliminated in this zone, and if preserved, will this tissue become a future pathological irritant?

WORKING LENGTH

Regrettably, endodontic working length, or the most apical cross-sectional diameter of a prepared canal, has been traditionally championed to be the CDJ. Yet, the CDJ is an irregular zone of infinite histological variability; as such, generations of dentists have been trained, based on statistical averages, to arbitrarily work 0.5 mm, or 1.0 mm, or even up to 2.0 mm short of the RT (Figure 7). Attempting to limit instrumentation to the CDJ is a flawed expectation further influenced by the concepts embraced, methods utilized, and abilities perfected. Globally, dentists who conscientiously work short of length universally report ending up shorter than were their intentions, especially in longer, narrower, and more apically curved canals (Figure 8).

Working short has resulted in countless canals that are apically and/or laterally blocked and hold residual irritants in their terminal extents.⁴ Worse, many dentists who work short, ill-advisably overprepare the terminal aspect of a canal to form an apical seat against which to pack obturation materials. It is ironic that a deliberately designed apical ledge is good, whereas a

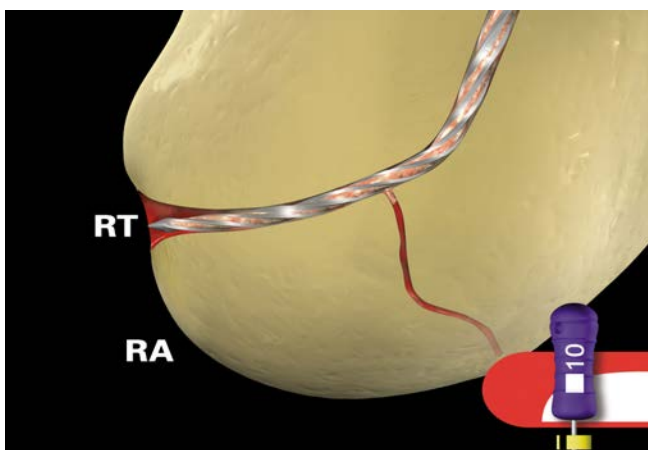


Figure 6. This image demonstrates a size 10 file at the RT and the most apical, dome-shaped aspect of the root, termed the radiographic apex (RA).

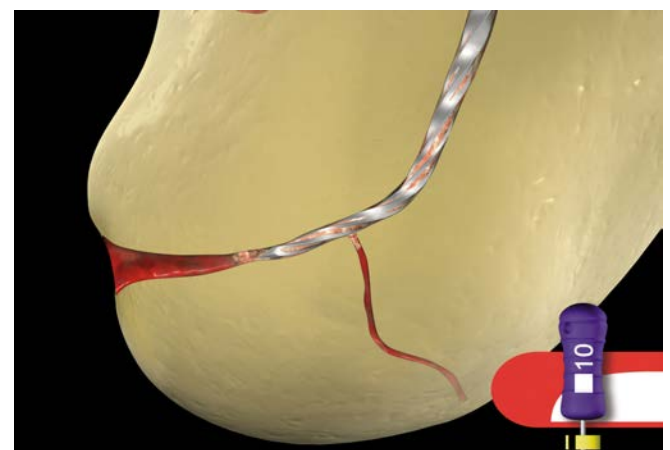


Figure 7. This image shows a small-sized file cutting dentin short of length. Note the initiation of a laterally and apically blocked canal.

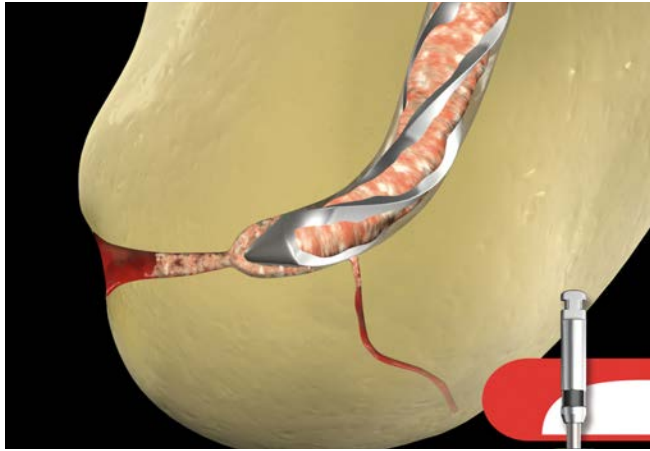

Figure 8. This image illustrates that preparing canals short oftentimes predisposes to a loss of working length and a canal that is blocked both apically and laterally.

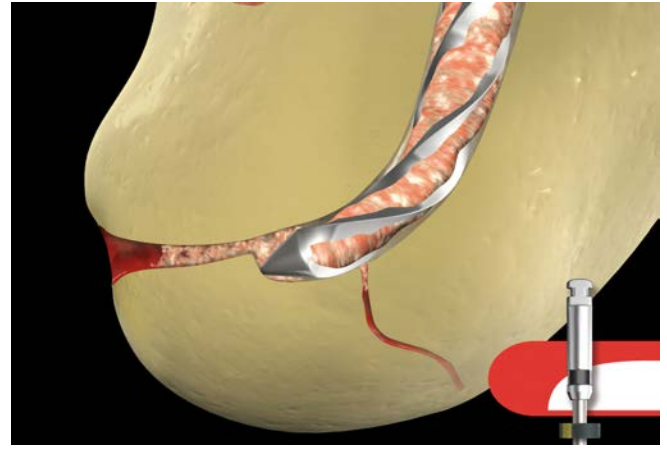


Figure 9. This image illustrates that preparing a canal short invites a block, which in turn, predisposes to an apical ledge.

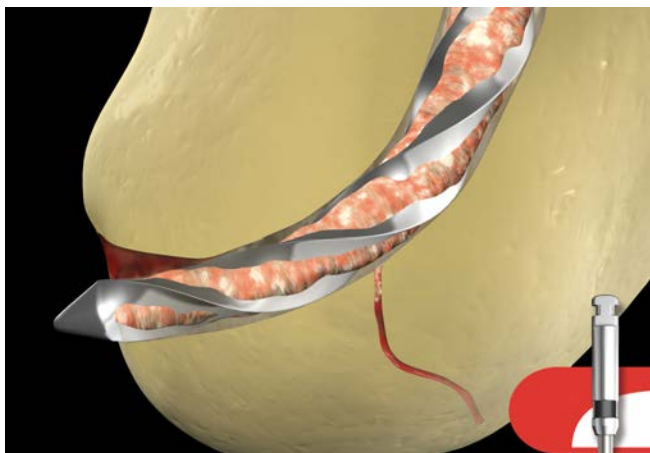


Figure 10. A graphic illustrates a transportation of the foramen, which results from carrying excessively large-sized and stiffer files to length.

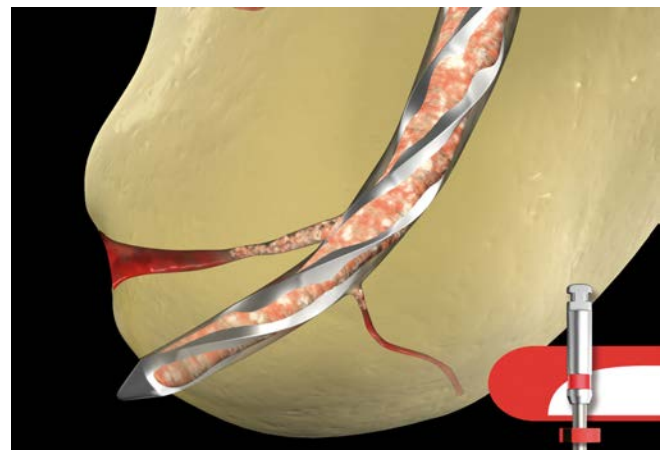


Figure 11. A graphic illustrates that an apically blocked canal predisposes to a ledge, which, if aggressively attacked, may result in an apical perforation.

ledge in a canal curvature is abhorrently bad. Even worse than a blocked and/or ledged canal is an apical perforation or transportation, which in the latter instance is relocating the foramen on the external root surface (*Figures 8-11*).⁴ These iatrogenic events have led to needless post-treatment exacerbations, wet canals, retreatments, and extractions.

The clinical breakthrough is to develop a canal preparation that vertically extends toward a universally attainable clinical landmark, the RT (*Figure 6*). This is encouraged, as the pathway of the canal can be precisely followed and maintained using heat-treated, highly flexible NiTi files that exhibit low shape memory. The concept is to develop a smooth-flowing and funnel-shaped preparation that emphasizes maintaining the anatomical position of the foramen on the external root surface and keeping this foramen as small as practical (*Figure 12*).⁵ These shaping objectives facilitate 3D disinfection while providing the apically tapered resistance form to maximize controlled hydraulics when filling root systems.⁶⁻⁸

Extending the depth of the preparation to the RT is analogous to a surgeon making a broad incision to ensure the complete

elimination of pathological tissue. Yet, preparing a canal to the RT does not necessarily represent the depth chosen for 3D obturation. To discover the optimal depth of obturation, a paper point is carried to the RT, removed, and inspected. The apical most extent of the paper point that is consistently clean, white, and dry represents the optimal, most apical level selected for obturation, termed the “physiological terminus” (PT) (*Figure 13*).⁹ The concept of mechanically extending the preparation ever closer towards the RT reduces the discrepancy, if any, between the RT and PT.

PATENCY

During the preparation procedure, pulpal remnants, necrotic tissue when present, and dentine mud are well known to accumulate, especially toward the constriction of any given canal. This cocktail of irritants predisposes to both apically and laterally blocked canals. To mitigate blocks, gently slide a highly flexible, small-sized file to and minutely through the RT. Then clear the foramen by moving this file in 0.5 mm–1.0 mm short vertical amplitude strokes until it is super loose.⁹ This action serves to break up debris, where it can be flushed from the

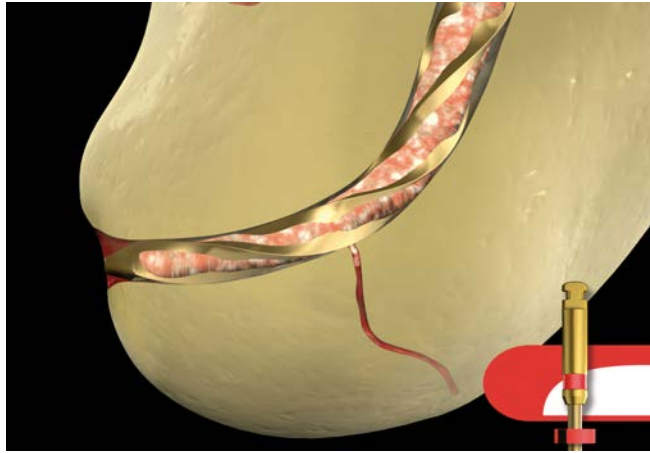

Figure 12. This graphic image depicts a NiTi, heat-treated, and highly flexible ProTaper Gold size 25/08 file precisely following curvature and at the terminus.

canal. Clinically maintaining apical patency is a nonissue when we reflect on the rich blood supply available external to the root, and hence, the capacity to heal.

GLIDE PATH

After establishing working length and confirming apical patency, it is wise to verify if there is a smooth, reproducible glide path to the RT to determine if it is safe to use mechanically-driven files.⁹ Traditionally, the glide path is verified and the canal is deemed secured when a stainless steel size 10 file can readily slip, slide, and glide along the length of the apical one-third of any given canal. However, with the emergence of dedicated, mechanical glide path files, GPM procedures, including patency, can generally be performed safer, easier, and faster with one single file.⁹ Root-appropriate shapes can be prepared once working length has been established, patency confirmed, and a glide path verified to the terminus of the canal.

ENDO 101 REVIEW

There is infinite anatomical variability within the terminal most aspect of any given canal. Even when the tip of the final file

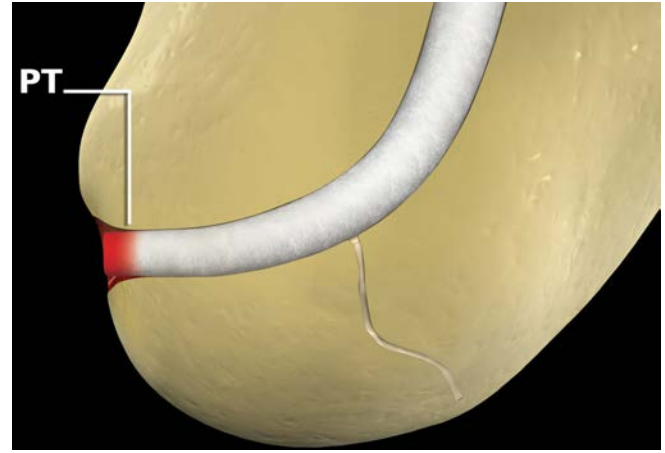


Figure 13. This graphic illustrates the paper point drying method to determine the optimal apical level for obturation.

is loose at the RT, appreciate a funnel-shaped preparation can be developed that automatically extends apical to the CDJ and ever closer toward the RT, depending on the D0 diameter and taper along the active portion of any given file (*Figure 14*). Just as shaping a canal serves to fortuitously shorten the length of a lateral canal, which encourages 3D cleaning, appreciate shaping also serves to shorten the discrepancy, if any, between the CDJ and RT. Shaping serves to project the smallest cross-sectional diameter of the preparation ever closer toward the foramen on the external root surface.

Histological evidence reveals that preparations enlarged to a size 40/06 are no cleaner than those enlarged to a size 20/10.¹⁰ Certainly, a size 25/08 file falls within these apical diameters and tapers, yet provides superior flexibility and resistance to cyclic fatigue as compared to a size 40/06 file of the same metallurgy. Of clinical importance, the D0 diameter of a size 25/08 file is 60% smaller than a size 40/06 file, which enables this considerably more flexible file to precisely follow apical curvatures. A size 25/08 file has cross-sectional diameters of 0.33 mm and 0.41 mm at D1 and D2, respectively. Strategically, when this file is carried to the RT, it will cut about the same cross-sectional diameters as a size 40/06 file carried 1.0 mm short (*Figure 15*).

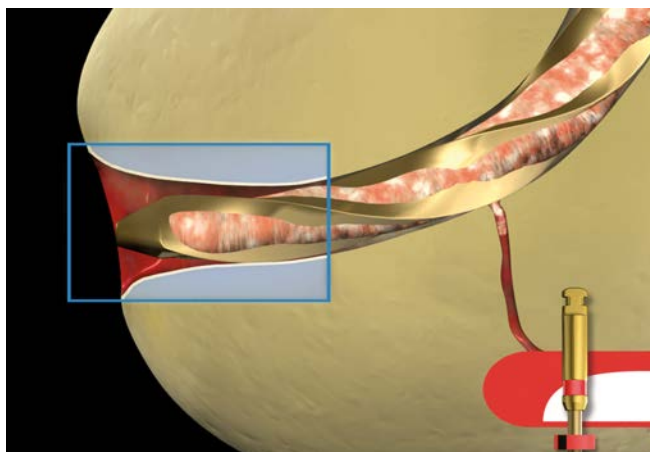


Figure 14. This graphic demonstrates that a sufficiently apically tapered file will extend a funnel-shaped preparation ever closer toward the ever-widening RT.

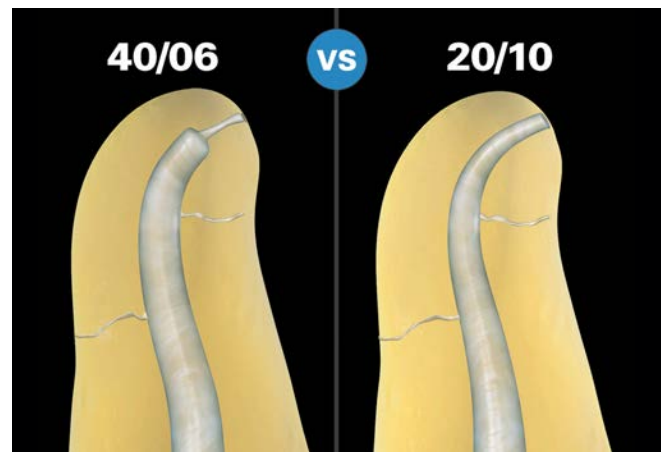


Figure 15. The left image illustrates the ill-advised apical box preparation 1.0 mm short. The right image illustrates a smooth-flowing shape to the terminus.

CLOSING COMMENTS

Endo 101 is a back-to-basics examination of the fundamental concepts that serve to guide each case toward a successful conclusion. It is empowering to grasp that the inner voice to which we choose to listen and feed directly influences the concepts on which we build and our capacity to grow. When we accurately apply the most relevant technologies to concept-guided procedures, success is maximized. Back to the question, which is more important, technology or concepts? The answer is both! Together, proven concepts and relevant technology enable clinical endodontics to be fun, efficient, and rewarding. ▲

REFERENCES:

1. Alothmani OS, Chandler NP, Friedlander LT: The anatomy of the root apex: a review and clinical considerations in endodontics, *Saudi Endod J* 3:1, pp. 1-9, 2013.
2. Kuttler Y: Microscopic investigation of root apexes, *J Am Dent Assoc* 50:5, pp. 544-552, 1955.
3. Seltzer S, Soltanoff W, Bender IB, Ziontz M: Biologic aspects of endodontics. I. Histologic observations of the anatomy and morphology of root apices and surrounding structures, *Oral Surg Oral Med Oral Pathol* 22: 375-385, 1966.
4. Ruddle CJ: Ch. 25, Nonsurgical endodontic retreatment. In *Pathways of the Pulp*, 8th ed., Cohen S, Burns RC, eds., St. Louis: Mosby, pp. 875-929, 2002.
5. Schilder H: Cleaning and shaping the root canal, *Dent Clin North Am* 18:2, pp. 269-296, April 1974.
6. Schilder H: Filling root canals in three dimensions, *Dent Clin North Am* pp. 723-744, November 1967.
7. Kanter V, Weldon E, Nair U, Varella C, Kanter K, Anusavice K, Pileggi R: A quantitative and qualitative analysis of ultrasonic versus sonic endodontic systems on canal cleanliness and obturation, *Oral Surg Oral Med Oral Pathol Oral Radiol Endod* 112:6, pp. 809-813, 2011.
8. Ruddle CJ: Ch. 9, Three-dimensional obturation: the rationale and application of warm gutta percha with vertical condensation. In *Pathways of the Pulp*, 6th ed., Cohen S, Burns RC, eds., St. Louis: Mosby Yearbook Co., 1994.
9. Ruddle CJ, Machtou P, West JD: Endodontic canal preparation: innovations in glide path management and shaping canals, *Dent Today* 33:7, pp. 118-123, July 2014.
10. Albrecht LJ, Baumgartner JC, Marshall JG: Evaluation of apical debris removal using various sizes and tapers of profile GT files, *J Endod* 30:6, pp. 425-428, 2004.